

14th European Congress of Toxicologic Pathology

**Adverse or Not Adverse –
Assessment and Consequences**



© Turisme de Barcelona / Jordi Trullàs

**20th – 23rd of September 2016,
Barcelona, Catalonia, Spain**

organized under the auspices of the European Society of Toxicologic Pathology



www.eurotoxpath.org



MEETING YOUR SCIENTIFIC AND BUSINESS NEEDS

Contact:

LPT Laboratory of Pharmacology and Toxicology GmbH & Co. KG

Redderweg 8, 21147 Hamburg, www.lpt-pharm-tox.de

Phone: +49 (0)40 70 20 20, Fax: +49 (0)40 70 20 22 99, e-mail: lpt@lpt-hamburg.de

SERVICES OFFERED BY LPT

- Single dose toxicity
- Repeated dose toxicity
- Reproduction toxicity
- Mutagenic potential
- Carcinogenic potential
- Immunotoxicity
- Local tolerance
- Neurotoxicity
- Cytotoxicity
- Safety Pharmacology
- Pharmacodynamics
- Pharmacokinetics
- Environmental Toxicology
- Analytical Chemistry
- Regulatory Affairs
- Literature searches
- Contract Archiving according to GLP

RESPONSIVENESS

- Direct access to Study Directors and Management
- 24-hour or less response
- Study issues reported to Sponsor within 24 hours (troubleshooting)
- >90% on-time delivery of draft reports

ADAPTABILITY – SPEED

- Experiments can very often be started as soon as possible (size of facility)
- Short period of time between co
- Completion of experiment and draft report
- 1 to 4 weeks between draft report and final report
- Interim reports
- Short-time period for proposal generation (less than 1 week)
- Flexibility: Willingness to customize processes, protocols and report templates
- Non-bureaucratic

SCIENTIFIC EXPERTISE

- More than 50 years of Expertise
- Low turn-over in workforce
- Most technicians are with LPT for more than 10 years
- Toxicologists, Study Directors and Histopathologists working in their fields for more than 10 years

SCIENTIFIC EXPERTISE

GENERAL FEATURES - QUALITY

- No expert report ever rejected by the authorities
- No study ever rejected by the authorities
- Passed all FDA inspections on GLP
- Passed all German GLP inspections

SCIENTIFIC EXPERTISE – GMP CONFIRMATION

- Since 2000 Regular GMP-Authority inspections
- Since 2009 FDA: Inspection of Botulinum Assay
Result: FDA approved
- Since 2010 GMP-Certificate according to § 14 (4) AMG by the local German
GMP-Authority for biological potency assays

Many Thanks to our exhibitors



Many Thanks to our sponsors



Welcome

Dear Colleagues and Friends,

The European Society of Toxicologic Pathology is pleased to welcome you to the **14th EUROPEAN CONGRESS OF TOXICOLOGIC PATHOLOGY** to be held in **Barcelona** at the Avenida Palace Hotel in the city center from the 20th to 23rd of September 2016.

A Scientific Committee comprising both nationally and internationally recognized experts is responsible for the preparation of the scientific program. This congress will focus on the assessment of adversity of different toxicopathological findings from various organs and the potential consequences for the development of a test item. The program will also include additional highly relevant topics of interest to both toxicologic pathologists and preclinical safety scientists. There will be plenary lectures, oral presentations of original scientific work, interactive case presentations, a half-day IATP session on juvenile toxicity with emphasis on the adverse and not adverse theme, poster sessions and of course plenty of opportunity for interactions both formally and informally with colleagues and friends. There will also be a trade exhibition where books, new equipment and techniques, contract laboratory services and much more will be presented.

Barcelona is the second most populated city in Spain and the capital of the autonomous community of Catalonia. Located on the northeast coast of the Iberian Peninsula, facing the Mediterranean Sea, this beautiful and friendly city offers its visitors a wide variety of cultural and gastronomic highlights including tapas, pintxos and vermouth. Impressive buildings can be found downtown: from the ancient remains of Roman settlements in El Born, to the many famous modernist works of Antoni Gaudí including his masterpiece, the still incomplete Sagrada Familia, and Park Güell.

For all participants, the social program will include a welcome reception on the roof terrace at the congress venue and a congress dinner at the Xalet de Montjuïc, with a panorama view at the top of the Montjuïc park.

We sincerely hope that the venue and Congress structure will provide you with an ambience to make your trip to Barcelona successful, inspiring, joyful and an experience to remember.

On behalf of the ESTP

Anna-Lena Frisk



Thierry Flandre



Chairs of the Scientific Organizing Committee

Table of Contents

Welcome	5
General Information	11
Scientific Organizing Committee	11
Local Organizing Committee	11
Congress Organizers.	12
Congress Venue	12
Registration Desk.	12
Speaker Information.	13
Poster Presentation	13
ESTP Interactive session	13
Abstract Publication	14
Awards	14
Industry Exhibition.	16
Exhibition Quiz.	16
Additional Meetings	17
Refreshments	17
Social Events	18
Messages.	19
Congress Bags	19
Safety and Security	20
Emergency calls	20
Currency	20
Congress Program.	21
5th ESTP International Expert Workshop: “Adversity of Lysosomal Accumulation”.	23
IATP Satellite Symposium on Juvenile Toxicity	24
A01: Robert Parker: Overview of toxicology and study design for juvenile toxicity	24
A02: George Parker & Catherine Picut: Postnatal Organ Development as a Complicating	25
Factor in Juvenile Toxicity Studies	25
A03: Darlene Dixon: Onset of uterine receptor expression in rats during development	25

Ao4: Paul Howroyd: Use of minipigs in juvenile toxicity studies	25
Ao5: Alys Bradley: Juvenile toxicity studies in non-human primates	26
Speaker Abstracts.	27
S01: Meador Vincent Phillip: Adversity Designation and Application to Drug Development .	27
S02: Rosenbruch Martin: Nose - Larynx - Lung: Methods - Findings - Assessment	31
S03: Piaia Alessandro: Non-neoplastic Lung Changes in Toxicological Studies and Adverse Definition	33
S04: Moulin Pierre: Translational pathology of lung toxicity	35
S05: Schumacher Vanessa, Benmansour Fethallah: Digital Pathology Solutions for Preclinical Assessment	37
S06: Klapwijk Jan and Barale Erio: Digital pathology in GLP environment	38
S07: Rosol Thomas J.: Comparative Pathophysiology of the Thyroid Gland: Human Relevance in Preclinical Toxicity Studies	39
S08: Freyberger Alexius: Compound-induced thyroid gland effects in rats - evaluation of mechanism and potential relevance for humans – the theory.	41
S09: Bach Ute and Rinke Matthias: Compound-induced thyroid gland effects in rats – Evaluation of mechanism and potential relevance for humans – the practice	42
S10: Schorsch Frederic: Adverse effects in the thyroid gland: examples out of Crop Science	43
S11: Hard Gordon: Renal Tubule Hyperplasia in Rats.	44
S12: Hard Gordon: Karyomegaly Versus Nuclear Enlargement	45
S13: Frazier Kendall: Adversity in the Kidney: Hyaline Droplets and Alpha-2u-globulin Nephropathy.	46
S14: Frazier Kendall: Adversity in the Kidney: Glomerulonephritis and Glomerulopathies. .	47
S15: Laurent Sébastien: Renal findings in a Cynomolgus monkey toxicity study with an oncology compound. Highest Non-Severely Toxic Dose (HNSTD), relevance for humans and benefit-risk ratio.	48
S16: Rinke Matthias and Bach Ute: Adverse or not adverse: Treatment-related findings in renal distal tubules and collecting ducts in Wistar rats	49
S17: Moulin Pierre: Translation Pathology of Kidney Toxicity	51
S18: Lenz Barbara: Comparison of investigative imaging techniques in drug-induced crystal nephropathy.	53
S19: Van Heerden Marjolein: Kidney pathology, evaluation of cisplatin-induced proximal tubular injury in Cynomolgus monkeys using laser ablation inductively coupled plasma-mass spectrometry.	54
S20: Pearse Gail: Adverse and non adverse changes in the lymphoid system	55

S21: Ruehl-Fehlert Christine: Adverse effects on the immune-system and beyond.	
Examples of immune effects in experimental animals and their relevance to humans.	56
S22: Ursula Junker: Pharmacological and adverse effects of immune modulators	
on the lympho-hematopoietic system. Example from rodents and non-rodents	57
S23: Kuper C. Frieke: Pattern recognition in complex systems to address	
adversity of effects on lymphoid organs and tissues.	59
S24: de Jonghe Sandra: Interactive slide session: adversity of some	
induced immunostimulatory histopathology findings	60
S25: Guionaud Silvia: Immunotoxicity in Drug Development: Mechanisms and	
Safety Assessment.	61
S26: Wieczorek Grazyna: A novel, blocking anti-CD40 monoclonal antibody	
prolongs non-human primate renal allograft survival in the absence of	
B-cell depletion or thromboembolic events.	62
S27: Tomlinson Lindsay: Adversity Considerations in Clinical Pathology	64
S28: Engelhardt Jeffery A.: Are proinflammatory effects of antisense	
oligonucleotides in animals a clinical cause for concern?	65
S29: Francke Sabine: “Overcoming adversity” – steps to addressing potentially adverse	
histopathology findings in documents intended for regulatory submissions to FDA.	67
S30: Lima Beatriz: Regulatory aspects of “adversity” in preclinical toxicity studies	68
S31: Wood Charles: Review considerations for agrochemicals – moving forward in the	
evaluation and communication of adversity	70
S32: Schulte Agnes: Industrial chemical-related thyroid tumors in rodents –	
we need a review of the CLP-criteria?	71
Case Presentations	73
CP01 Franck Chanut: Adversity, Highest Non-Severely Toxic Dose (HNSTD) and	
Risk Assessment in the context of a cynomolgus monkey study	73
CP02 JoAnn C.L. Schuh: Hard-Hearted Hounds	75
CP03 Heike Marxfeld: Treatment-related vacuolation in Wistar rats in	
90 day (gavage) studies – adverse or not?	77
CP04 Lars Mecklenburg: An example of nephrotoxicity in a Cynomolgus	
monkey treated with an Antibody-Drug Conjugate.	79
Poster Abstracts	81
P01: A possible antitumoral effect of exercise-training on lesions induced	
by 1-Methyl-1- Nitrosourea in a rat model	81
P02: Genetic Toxicity Battery of Perillaldehyde	83
P03: Busulfan-induced non-proliferative lesions in a mouse time course study	84

P04: A 26-week carcinogenicity study of FMS3 in rasH2 transgenic mice	85
P05: Histological and immunohistochemical characterization of Sunitinib efficacy on A498 human renal cell carcinoma xenografts in athymic nude CD-1 female mice.	86
P06: Expression of molecules showing promoter region hypermethylation in the liver of rats treated with Thioacetamide for 28 days using a two-stage hepatocarcinogenesis model.	88
P07: In vivo reporter gene mutation and micronucleus assays in gpt delta mice treated with the flame retardant decabromodiphenyl ether	90
P08: Comparison between developmental and post-pubertal stage exposure to N-methyl-N-nitrosourea on the effect of rat hippocampal neurogenesis	91
P09: Molecular mechanisms of cell proliferation contributing to the mutagenicity of estragole, a hepatocarcinogen	93
p10: Histological characteristics of spontaneous Glutathione S-Transferase placental form (GST-P) positive foci of hepatocellular alteration in male SD rats.	94
P11: Immunohistological investigation of genotoxicity, cell proliferation and apoptosis induced by inhalation of nanoscaled cerium oxide or barium sulfate	95
P12: Immunohistochemical characterization of immune system tumors in rasH2 mice	96
P13: The use of in vivo and ex vivo compact magnetic resonance imaging (MRI) for the assessment of tumorigenicity following intrathecal transplantation of human embryonic stem cells (hESC) in NOD-SCID mice	97
P14: Investigating small molecule liver toxicity by Matrix-Assisted Laser Desorption/Ionization-Image Mass Spectrometry (MALDI-IMS).	98
P15: Molecular target validation in human atherosclerosis based on mass spectrometry imaging and immunohistochemistry studies	99
P16: Optical imaging techniques to monitor stem cell distribution in preclinical applications	101
P17: Tissue Mass Spectrometry Imaging as a tool for drug candidate selection: tissue distribution and relationship to toxicity.	102
P18: Examples of Drug-Related Immune Effects in Preclinical Toxicological Studies and Clinical Studies Based on a Data Search in the Pharmapendium ® Database	103
P19: Safety assessment of T cell bispecific antibodies targeting FOLR1 in cynomolgus monkeys	104
P20: Trauma as a cause for hepatopathy in newborn Göttingen minipigs: a procedure-related finding complicating interpretation of toxicity studies.	105
P21: The evaluation of intestinal toxicity caused by indomethacin in zebrafish (Danio rerio).	106
P22: Silver nanoparticles: assessment of bactericidal activity against Aeromonas salmonicida and in vitro cytotoxicity using the MTT assay in three different fish cell lines	108



Find a Better Path

with Charles River, your partner for integrated anatomic and clinical pathology services, from discovery to regulatory approval

P23: The minipig: an alternative animal model for the evaluation of anti-neoplastic drugs	109
P24: Always know your vehicle: sulfuric-acid based vehicle induced nephrotoxicity and pancreas toxicity in cynomolgus monkeys.	110
P25: Comparison of Green Fluorescent Protein (GFP) fluorescence intensity and tissue quality using two fixation methods by immersion	111
P26: Use of a multiple low dose regimen of non-pharmaceutical grade streptozotocin results in consistently elevated blood glucose levels and a lower incidence and severity of detectable, clinical effects in male C57BL/6 mice when given intraperitoneally	112
P27: An in vivo chicken model for fluoroquinolone-associated degenerative tendinopathy.	113
P28: Interpreting elevations of cardiac troponins using high sensitivity cardiac troponin (hs-cTn) assays in preclinical toxicology. When is an elevation adverse?.	115
P29: Spontaneous age-related lesions of rat kidney fornices.	116
P30: Case report: congenital superior ectopic kidney in a cynomolgus monkey	117
P31: The route of exposure influences nasal lesion distribution in rats in NTP Studies.	118
P32: PEG accumulation in cells: adverse or non-adverse?.	119
P33: Changes in preclinical liver biological data in a Clofibrate toxicity study in male Wistar rats: adverse or not adverse?	120
Exhibitors & Sponsors	121

General Information

Scientific Organizing Committee

Aïda Diaz-Bayon
Charles River, UK



Alessandro Piaia
Novartis, Switzerland



Annabelle Heier
Novartis, Switzerland



Anna-Lena Frisk
Bayer Pharma AG,
Germany



Begonya Garcia
Charles River, UK



Bob (Robert) Maronpot
Maronpot Consulting LLC,
USA



Céline Thuilliez
Institut de Recherche
Pierre Fabre, France



Erio Barale-Thomas
J&J PRD, Belgium



Gabriele Pohlmeier-Esch
Kaleidis – Consultancy,
France



Grazyna Wiczorek
Novartis, Switzerland



Matthias Rinke
Bayer Pharma AG,
Germany



Neus Prats Costa
IRB-Barcelona –
Institute for Research in
Biomedicine, Spain



Rainer Ernst
Bayer Pharma AG,
Germany



Sébastien Laurent
Sanofi, France



Serge Zander
Covance, UK



Sibylle Groeters
BASF SE, Germany



Thierry Flandre
Novartis, Switzerland



Ute Bach
Bayer Pharma AG,
Germany



Local Organizing Committee

Neus Prats Costa
IRB-Barcelona –
Institute for Research in
Biomedicine, Spain



Jordi Aluma Grau
Patconsult. BCN S.L.,
Spain



General Information

Congress Organizers

Solution office e. K.

Bergstr. 2
29646 Bispingen
Germany

Phone: +49 5194 – 97 44 90
Fax: +49 5194 – 97 44 94
e-mail: pia.schroeder@solution-office.de



Congress Venue

Hotel Avenida Palace

Gran Vía de les Corts Catalanes 605
08007 Barcelona
Spain

The Avenida Palace Hotel is situated in the city center of Barcelona, in the northeast of Spain at the Mediterranean Sea. Barcelona can be reached by plane, rail and road.

The Avenida Palace Hotel is situated in the city center of Barcelona, in the northeast of Spain at the Mediterranean Sea. Barcelona can be reached by plane, rail and road.

Google Maps: <https://goo.gl/maps/ehHpd3zP3A42>
Website: <http://www.avenidapalace.com/en/>

The Meeting will be held in the „Gran Salon“ in the Congress area on the first floor of the hotel. Poster hall, exhibition, coffee and lunch area will be located in the same area.

Registration Desk

The desk will be located on the first floor in the foyer. All the congress documents can be picked up from the registration desk. An identification badge must be worn to enter all the congress sessions and events. Please remove your name badge when leaving the congress area.

Registration is possible during the whole congress.

Opening hours of the registration desk:

Tuesday, 20th September 2016	09:00 am – 05:00 pm
Wednesday, 21st September 2016	08:00 am – 05:00 pm
Thursday, 22nd September 2016	08:00 am – 05:00 pm
Friday, 23rd September 2016	08:00 am – 12:00 pm

General Information

Registration for the IATP satellite meeting:

Tuesday, 20th September 2016 07:00 am – 08:00 am

The Registration desk is kindly sponsored by



Speaker Information

Video projector and PC are available for presentations. Please hand over your presentations to the technic desk in the back of the plenary room (Gran Salon) at the latest during the last break before your session. Please bring your presentation on an USB stick. The use of your own PC is not recommended. Electronic voting devices will be available for the audience for interactive presentation.

Poster Presentation

Posters will be exhibited during the entire Congress. Poster sessions are scheduled during coffee and lunch breaks.

Authors are kindly requested to be at their posters during the poster sessions during the coffee break on Wednesday afternoon, 15:15 to 16:00 and during the lunch break on Thursday, 12.30 to 14:00 to answer potential questions. There will also be interactive posters, where you will have the possibility to actively express your opinion on the poster, and we are looking forward to lively discussions.

The poster boards are kindly sponsored by



ESTP Interactive session

Interactive sessions on different cases of toxicologic pathology are organized during the whole congress. Electronic voting devices will be available for the audience for these interactive sessions.

General Information

Abstract Publication

Presentations given at this congress will be posted in pdf-format on the ESTP society website in the member's only section. An USB Stick with all the presentations (pdf format) from the meeting will be prepared by the organizers and sent to participants after the congress. The USB-Stick is an official publication with an ISBN number.

Awards

The congress program will also include the following awards:

Chirukandath Gopinath Lecture Award sponsored by the British Society of Toxicological Pathology (BSTP)

The award (engraved glass award), instigated by the British Society of Toxicological Pathology in 2008, was due in part to the BSTP's involvement in the organization of the scientific program of the 2008 Annual ESTP Congress held in Edinburgh. To mark the occasion, the BSTP sponsored the keynote lecture and since then this sponsorship has become a tradition at the ESTP Congresses.

The sponsored lecture was called the BSTP Chirukandath Gopinath Lecture in tribute to one of the founder members of the BSTP whose name is recognized by toxicological pathologists all over the world. The lecture is to be on a topic in pathology relevant to practicing toxicological pathologists. The speaker is an internationally recognized scientist and is chosen by the scientific organizing committee and approved by the BSTP council.




Award for the Best Poster sponsored by the French Society of Toxicologic Pathology (SFPT)

Since 2010, the French STP sponsors the 2 Best Poster Awards selected by the Poster Committee with a diploma and a monetary prize of € 1000,-. The aim of the SFPT is to help scientists to share their work and results to their scientific peers and to favor direct contact during the poster sessions. All posters with pathology content are eligible; however toxicologic pathology topics will be favored and one award will more specifically be offered to a young colleague.



IATP Charles Capen Trainee Award, rewarding a major contribution in toxicologic pathology by a student or trainee

The Charles Capen Trainee Award given by the International Academy of Toxicologic Pathology (IATP) recognizes Dr. Charles Capen and his legacy as a researcher, teacher, and mentor to the pathology and toxicology communities spanning more than



General Information

four decades. Dr. Capen was recognized worldwide as an exceptional leader in veterinary and biomedical research. He was a highly regarded mentor to numerous graduate students and postdoctoral scientists. His students and trainees are now leaders throughout academia, government and industry.

The Charles Capen Awards provides a classic reference book to the awardee to further his or her training and education in the field of toxicologic pathology.

The successful applicant must be a pathology, toxicology or toxicologic pathology trainee. A trainee is defined as an individual working on an academic degree, in a training or residency program, or in a postdoctoral training position and have demonstrated achievements in the field of toxicologic pathology including but not limited to:

Research contributing to public safety as it relates to the adverse health effects of xenobiotics; establishing test methods and standards that enhance the field of toxicologic pathology; and/or developing new or novel uses of toxicologic pathology in safety research.

ESTP Thesis Award, sponsored by ESTP

This award consists of first, second and third prize with award certificate, prize money 1st € 2000,-, 2nd € 1500,-, 3rd € 1000,- and one year free ESTP membership. With this endowment it is attempted to promote cooperation between Universities and industry and to interest young scientists in toxicological pathology and related fields.



Doctoral theses or PhD-theses on any aspect of toxicologic pathology, laboratory animal pathology or experimental pathology will be considered for an award. Applicants have to be enrolled in a European University. Theses have to be written in English or the applicant must be willing to arrange for translation if requested. Theses of the two previous years are considered.

IFSTP Trainee Award

IFSTP (International Federation of Societies of Toxicologic Pathologists) is a confederation of ten national and regional societies of toxicologic pathology (STPs) representing scientists from around the globe. The IFSTP's stated role is to build, integrate and set standards in toxicologic pathology. Its activities are controlled by the member STPs, which provide funds and volunteers to conduct IFSTP functions.



IFSTP has established a trainee award for PhD students training in toxicologic pathology. The IFSTP will fund an award in the amount of \$ 750 – USD, which can be used by the successful student for travel or registration costs to attend the ESTP conference.

The award ceremony is scheduled for Thursday, 22nd of September, during the Congress Dinner, with the exception of the BSTP Lecture Award, which will be presented prior to its respective talk.

General Information

Industry Exhibition

As in previous years, an exhibition featuring Pharmaceutical and Product Companies, Technical Equipment Companies and Medical Publishers will be held at the conference. Entrance is free to those registered for the Conference and registered accompanying persons.

The exhibition will open on Wednesday, September 21st, at 09.30 am and will then follow the same schedule as the conference and will close after the afternoon coffee break of Thursday, September 22nd.

The industry exhibition provides information about the newest technologies and developments available within our scientific area. The ESTP values the support provided by exhibitors and believes that the on-site discussion and exchange of experience between exhibitors and the congress participants is of invaluable importance and benefit.

Please visit our exhibitor booths!

Exhibition Quiz

There will be an exhibition quiz and you will receive details on how to participate when you register for the meeting. There are different prices which will be presented on Thursday before the afternoon coffee break.

The prize is kindly sponsored by



General Information

Additional Meetings

ESTP Scientific Organizing Committee 2017 Meeting (upon invitation)

The meeting will be held in room “Dorado” on Wednesday, September 21st, 12.20 to 13.40.
Lunch and coffee will be provided

International STPs Presidents F2F Meeting and TC (upon invitation)

This meeting will take place in room “Parrilla” on Wednesday, September 21st, 18.15 to 19.15.
Softdrinks and coffee will be provided.

CSS Meeting

Wednesday, September 21st, 18.15 to 19.15
Room: Parilla

Pathology 2.0 F2F Meeting and TC (upon invitation)

The meeting will be held in room “Dorado” on Wednesday, September 21st, 18.15 to 19.15.
Coffee will be provided

ESTP Executive Committee F2F Meeting and TC (upon invitation)

The meeting will be held in room “Dorado” on Thursday, September 22nd, 12.30 to 13.30.
Lunch and coffee will be provided.

ESTP Annual General Assembly

The society’s AGA will be held in the Gran Salon on Thursday, September 22nd, from 17.00 to 19.00.

Refreshments

Coffee, tea, soft drinks and pastries will be served during the coffee breaks.

Lunch is provided during the lunch breaks on:
Wednesday, September 21st
Thursday, September 22nd

One coffee break is kindly supported by



General Information

Social Events

Welcome Reception – Tuesday, 20th September 2016, 19.15 h – 21.00 h

On the evening of Tuesday, 20th September, we would like to invite you to join us at the Welcome Reception.

The Reception will take place on the roof terrace of the congress hotel where you will have the opportunity to meet colleagues and friends, to chat and prepare yourself for the following days of the conference.

Join us, have a drink and enjoy the great views over the city of Barcelona.

Address: **Hotel Avenida Palace**
Gran Vía de les Corts Catalanes 605
08007 Barcelona

Roof terrace „El Altillo“

Google Maps: <https://goo.gl/maps/N2GpkmJNTJC2>

Drinks and snacks will be provided.

The Welcome Reception is kindly supported by



Conference Dinner – Thursday, 22nd September, 20.00 h - late

The Conference dinner will take place in Xalet de Montjuïc on Thursday, 22nd September.

You are invited to enjoy a delicious dinner and to meet friends and colleagues in a relaxed atmosphere. Xalet de Montjuïc is a round restaurant with a large panorama window on top of the Montjuïc park. Its special feature is that the room revolves very slowly so that anyone sitting near a window will have the chance to enjoy the views of Barcelona. This is the perfect opportunity to relax and reflect on the congress and engage in spirited conversation.

Address: **El Xalet de Montjuïc**
Avinguda de Miramar 31
08038 Barcelona

„Revolving room“

Google Maps: <https://goo.gl/maps/w2qmmAx05ko>

Dress Code: Business casual

General Information

A shuttle from the conference venue and back will be provided. It is also possible to use the metro and the funicular up to the Montjuïc which is a special experience. Please note that you need to organize this by yourself.

Shuttle times: 19.45 Avenida Palace Hotel to El Xalet de Montjuïc

For the way back we provide commuter traffic between El Xalet de Montjuïc and Avenida Palace Hotel starting after the dessert. For those who stay longer: No worries - The last shuttle will be announced.

Messages

There is a message board close to the congress registration desk.


Congress Bags

Congress bags can be picked up at the registration desk.

The bags are kindly sponsored by



TPL
Pathology Labs R&D



General Information

Safety and Security

Please, wear your name badge while in the congress area (access will be denied otherwise). Remove your name badge when leaving the congress area.

The name badges are kindly sponsored by



The lanyards are kindly sponsored by



In case of emergency, please follow directions from the congress staff and chair persons.

Emergency calls

Police, Ambulance, Fire: **112**

Operators for the Pan-European emergency number (112) speak English and will contact the appropriate emergency service. Calling 112 is free from any telephone (mobile cellular or fixed-line).

Currency

The currency in Spain is the Euro (€), divided into 100 Cent.

Since the launch of the Euro there are not that many exchange offices anymore, but credit cards are accepted almost everywhere. Note that most institutions charge a fee for the use of the card in foreign countries. Please check your contract.

Congress Program

Tue 20 Sept	Wed 21 Sept		Thu 22 Sept		Fri 23 Sept	
Registration/IATP session. Juvenile toxicity	Seesion 2. Thyroid adversity	S. Groeters A. Heier	Session 4. Lympho-hematopoietic system adversity	A-L Frisk S. Zander	Session 6. Regulatory expert panel	G. Pohlmeier-Esch X. Palazzi
	Keynote. Comparative Pathophysiology of the Thyroid Gland. Human Relevance in Preclinical Toxicity Studies 8.30-9.15	Tom Rosol	Keynote. Adverse and non adverse changes in the lymphoid system (interactive lecture) 8.30-9.15	Gail Pearce	“Overcoming adversity” – steps to addressing potentially adverse histopathology findings in documents intended for regulatory submissions to FDA (interactive lecture) 8.30-9.15	Sabine Francke
	Compound-induced thyroid gland effects in rats – Evaluation of mechanism and potential relevance for humans - the theory 9.15 - 9.50	Alexius Freyberger	Example out of Pharma. „Adverse effects on the immune-system and beyond. Example of immune effects in rodents and relevance to humans“ 9.15-9.45 Example out of Pharma. „Pharmacological and adverse effects of immune modulators on the lympho-hematopoietic system. Example from rodents and non-rodents“ (interactive lecture) 9.45-10.15	Christine Rühl-Fehlert Ursula Junker	Regulatory aspects of „adversity“ in preclinical toxicity studies 9.15-10.00 Review considerations for agrochemicals – moving forward in the evaluation and communication of adversity (interactive lecture) 10.00-10.45	Beatriz Lima Charles Wood
	Break 9.50-10.20		Break 10.15-10.45		Break 10.45-11.15	
	Seesion 2b. Thyroid adversity and Kidney	S. Groeters A. Heier	Session 4b. Lympho-hematopoietic system adversity and Special/New Techniques (Path 2.o)	B. Garcia S. Zander	Session 6b. Regulatory expert panel / Interactive case presentation	G. Pohlmeier-Esch X. Palazzi
	Example out of Pharma: „Compound-induced thyroid gland effects in rats – Evaluation of mechanism and potential relevance for humans – the practice“ (interactive lecture) 10.20-10.50	Ute Bach Matthias Rinke	Gopinath lecture award: „Pattern recognition in complex systems to address adversity of effects on lymphoid organs and tissues“ (interactive lecture) 10.45-11.15	Frieke Kuper	Industrial chemical-related thyroid tumors in rodents - do we need a review of the CLP-criteria? 11.15-12.00	Agnes Schulte
	Example out of Chemie. „Adverse effects in the thyroid gland. examples out of Crop Science“ (interactive lecture) 10.50-11.20	Frédéric Schorsch	„Interactive session to discuss the adversity of some induced immunostimulatory histopathology findings“ (interactive lecture) 11.15-11.30	Sandra de Jonghe Frieke Kuper		

Congress Program

Tue 20 Sept		Wed 21 Sept		Thu 22 Sept		Fri 23 Sept	
		INHAND update 11.20- 11.30	Thomas Nolte	Example out of Pharma: „Immunotoxicity in Drug Development. Mechanisms and Safety Assessment“ 11.30-12.00	Silvia Guionaud	Interactive Posters on adversity. 1. PEG accumulation in cells, case example; 2. Increase of liver biomarkers without microscopic hepatocellular injury; 12.00-12.20	Annamaria Braendli-Baiocco Pierre Maliver
		Tubule hyperplasia in rats (interactive lecture) 11.30-11.55 Karyomegaly vs nuclear enlargement (interactive lecture) 11.55-12.20	Gordon Hard	Pathology 2.o. “A novel, blocking anti-CD40 monoclonal antibody prolongs non-human primate renal allograft survival in the absence of B-cell depletion or thromboembolic events” 12.00-12.30	Grazyna Wieczorek	Interactive case presentation (Marxfeld, Chamut) 12.20-13.00	2 slots 2X20 min
Welcome, Introduction and Exhibitors presentations 12.45-13.15		Lunch 12.20 - 13.40		Lunch 12.30-14.00 Poster Session with presence of authors		Concluding remarks - meeting close at 13.15	
Session 1. Adversity introduction and lung adversity	T. Flandre N. Prats Costa	Session 3. Kidney adversity	A. Piaia S. Laurent	Session 5. Lympho-hematopoietic system adversity	A-L Frisk B. Garcia		
Keynote. Adversity Designation and Application to Drug Development 13.15-14.15	Vince Meador	Adversity in the Kidney. Hyaline Droplets and Alpha-2u-globulin Nephropathy (interactive lecture) 13.40 - 14.05 Adversity in the Kidney. Glomerulonephritis and Glomerulopathies (interactive lecture) 14.05 -14.30	Kendall Frazier	Adversity Considerations in Clinical Pathology (interactive lecture) 14.00-15.00	Lindsay Tomlinson		
Nose-Larynx-Lung . Methods-Findings-Assessment 14.15-15.00	Martin Rosenbruch	Example out of Pharma: „Renal findings in a Cynomolgus monkey toxicity study with an oncology compound. Highest Non-Severely Toxic Dose (HNSTD), relevance for humans and benefit-risk ratio“ (interactive lecture) 14:30-14:45	Sébastien Laurent	Are proinflammatory effects of antisense oligonucleotides in animals a clinical cause for concern? 15.00-15.45	Jeff Engelhardt Grazyna Wieczorek (30 min)		
Non-neoplastic Lung Changes in Toxicological Studies and Adverse Definition 15.00-15.45	Alessandro Piaia	Example out of Pharma. „Adverse or not adverse. Treatment-related findings in renal distal tubules and collecting ducts in Wistar rats“ (interactive lecture) 14.45-15.15	Matthias Rinke Ute Bach	Pathology 2.o part III. “Anti-CD40 therapy in non-human primate kidney transplantation model”. 16:00-16:30			

Congress Program

Tue 20 Sept		Wed 21 Sept		Thu 22 Sept		Fri 23 Sept	
Break 15.45-16.15		Break 15.15-16.00 Poster Session with authors		Break 15.45-16.15			
Session 1b. Lung Adversity and Special/ New Techniques for Risk assesment (Pathology 2.0)	T. Flandre G. Wiczorek	Session 3b. Kidney adversity and Special/ New Techniques (Pathology 2.0)	A. Piaia S. Laurent	Session 5b. Interactive case presentation	S. Groeters		
Translation Pathology of Lung Toxicity 16.15-17.00	Pierre Moulin	Translation to human/ risk assessment - Translation Pathology of Kidney Toxicity 16.00-16.45	Pierre Moulin	Interactive case presentation (Mecklenburg, Schuh) 16.15-17.00	2 slots 2X 20 min		
		Pathology 2.0. „Comparison of investigative imaging techniques in drug-induced crystal nephropathy“ 16.45-17.30	Barbara Lenz Marjolein van Heerden				
Pathology 2.0 „Digital pathology solutions for preclinical assessment“ 17.00-17.30	Vanessa Schumacher	“Kidney pathology, evaluation of cisplatin-induced proximal tubular injury in Cynomolgus monkeys using laser ablation inductively coupled plasma-mass spectrometry” 16.45-17.30	Marjolein van Heerden Barbara Lenz	ESTP AGM 17.00 -19.00			
Digital pathology in GLP environment 17.30-18.00	Jan Klapwijk Erio Barale	Panel expert question 17.30-18.00	G Hard, K Frazier, P Moulin. Moderator: Jan Klapwijk				
Welcome reception 19.15 with the exhibitors				Conference Dinner 20.00			

5th ESTP International Expert Workshop: “Adversity of Lysosomal Accumulation”

After months of preparatory teleconferences, the face-to-face workshop comprising over 20 expert members, among which six scientists from international regulatory agencies, will take place immediately after the congress, starting at 13.00 on Friday, September 23rd, and lasting the full day of Saturday, September 24th. An audience of approximately 25 interested pathologists/toxicologists, who have registered via the ESTP website, will participate at this event.

IATP Satellite Symposium on Juvenile Toxicity

This 4-hour session will provide an overview of study design and testing methods in juvenile toxicity followed by presentations of toxicity and pathology responses in rodents, minipigs, and non-human primates. The focus will be on the relevance and challenges of responses in these studies to toxicologists and pathologists with presentation of tissue pathology and identification of adverse responses in these animal models.

Ao1: Robert Parker: Overview of toxicology and study design for juvenile toxicity

Juvenile toxicology is complicated due to the dynamic anatomic and physiological changes that occur during growth and development of an individual. Non-clinical juvenile toxicity studies are logistically complicated due to the design of study and their size, the number, diversity and interdependence of endpoints based on target organ development, the myriad modes of actions that need to be evaluated, and the constraints (e.g., route of administration, necropsy techniques, blood collection, behavioral assessments) due to the physical size of the animal and its growth during the study. Rodents are the most common species tested in juvenile toxicity studies due to a number of factors including the extensive experience and historical data across labs and the ability to test the full span of postnatal development. However, there are limitations as well, which can present challenges to designing and executing successful studies. Factors unique to juvenile toxicity studies present a challenge to the drug development team. The study design should consider target organ, species and age relevant organ development, PK/ADME, and pharmacology. This talk will address some of the considerations and challenges associated with rodents in conducting and interpreting data derived from juvenile toxicity studies and will include examples based on industry experience.

*IATP Satellite Symposium on Juvenile Toxicity***A02: George Parker & Catherine Picut: Postnatal Organ Development as a Complicating Factor in Juvenile Toxicity Studies**

In performing the histopathological evaluation on studies conducted in juvenile animals, the pathologist is presented with challenges related to variable states of postnatal tissue development. The histologic evidence of tissue immaturity must be distinguished from pathological alterations attributable to test article administration or other aspects of experimental manipulation. These issues become particularly acute in the evaluation of unscheduled death animals, as typical toxicology studies have no concurrent controls for comparison to early decedents. This seminar is based on an organized histological study of postnatal organ development in laboratory rats, commencing on the day of birth and extending through postnatal day 42. Emphasis will be placed on tissues that undergo pronounced postnatal development, particularly the reproductive and immune system organs, and organs with histological features that are most easily confused with pathological alterations.

A03: Darlene Dixon: Onset of uterine receptor expression in rats during development

With growing concern of environmental chemicals adversely affecting human health and the prospect of in utero and early developmental exposures, there is increasing use of early-exposure testing paradigms in preclinical studies. Many of these studies require the use of immature female rats, making it increasingly important to know the onset and expression patterns of hormone receptors in the developing uterus, which may be the target of endocrine-disrupting chemicals. Also, delineation of mechanisms through which “hormone mimics” or related xenobiotics may adversely affect normal uterine growth and development, or induce developmental lesions in this organ, requires that hormone receptor-positive cell populations be identified and their patterns of expression characterized in situ. This presentation will assess the distribution and expression of hormone receptors in the uterus of rats during postnatal development.

A04: Paul Howroyd: Use of minipigs in juvenile toxicity studies

Minipigs are being used increasingly in juvenile toxicity studies, as they have several advantages over alternative non-rodent species. This presentation will outline how they are used in juvenile toxicity studies and will illustrate important normal histological features and pathological changes seen in juvenile minipigs.

*IATP Satellite Symposium on Juvenile Toxicity***A05: Alys Bradley: Juvenile toxicity studies
in non-human primates**

This presentation will provide an overview of the use of Non-Human Primates in Juvenile toxicity studies. The most common Non-Human Primate models will be described along with advantages and challenges of using Non-Human Primates for these types of studies, e.g. supply of animals of the number, gender mix and age required. Study designs will be discussed in terms of measurable endpoints of in life data (e.g. behaviour, safety pharmacology) and terminal procedures (e.g. necropsy, specialised histopathology, immunophenotyping).



Speaker Abstracts

So1: Adversity Designation and Application to Drug Development

Meador Vincent Phillip, DVM, PhD, Diplomate ACVP
Pacific Tox Path, LLC



The no-observed-adverse-effect-level (NOAEL) is an important part of non-clinical risk assessment for determining safe exposures of test articles to humans in drug development, additives in food, and chemicals which may access the environmental chemical safety. It is derived from studies in laboratory animals and is intended to communicate the highest dose tested of a substance at which nothing adverse (i.e., harmful) happens. The NOAEL determines and communicates both the potential hazard(s) of a substance, along with the potential risks to humans under defined conditions, by comparing the dose at which these effects occur in animal model systems with known or estimated human exposures.

As simple as the concept of NOAEL appears, its effectiveness has been lessened by varied and inconsistent definition, application and communication. The common definition of NOAEL, "the highest experimental point that is without adverse effect," serves well in general discussions, but its fidelity frequently breaks down based on 1) lack of a universally accepted definition of adverse as it applies to NOAEL, 2) the criteria that makes an effect adverse, 3) the boundaries to which those criteria are applied, and 4) inadequate communication as to the rationale by which an effect is or is not adverse. The center of the inconsistency often emanates from assigning adversity beyond what the test system definitively supports (i.e., was the effect adverse or non-adverse to the animal(s) within the study that the NOAEL was established?), and inadequate communications for understanding by the intended audience. Various authors have made progress in bringing conformity and effectiveness to the topic by proposing a definition of 'adverse', its application in setting the NOAEL, and approaches for usage. (Lewis et al. 2016, Keller et al. 2012, Dorato and Engelhardt 2005).

Given the importance of the NOAEL approach in protecting human safety, efforts to bring clarity and consistency to 'Adversity' have been recently renewed by both the Society of Toxicologic Pathology (STP) and the European Society of Toxicologic Pathology (ESTP) working as distinct, but linked and collaborative entities.

Recommendations (best practices) were provided and published by the STP Adversity Working Group for making consistent interpretations of test article-related effects as "adverse", and assigning a NOAEL in nonclinical toxicity studies (Kerlin et al. 2016). To allow focus on the recommendations, this group simply defined adverse as a term indicating "harm" to the test animal, while non-adverse indicates 'lack of harm'. Their 10 recommendations are a hierarchical grouping into 3 categories of determining, communicating and applying adverse and NOAEL.

Speaker Abstracts

Determining Adverse and “NOAEL”

- Recommendation 1: Adversity is a term indicating harm to the test animal.
- Recommendation 2: The decision about whether or not test article–related effects (or a group of related effects) in a nonclinical study are considered adverse or non-adverse should be unambiguously stated and justified in sub-reports and/or the study report.
- Recommendation 3: Adversity as identified in a nonclinical study report should be applied only to the test species and under conditions of the study.
- Recommendation 4: Toxic effects on cells, tissues, organs, or systems within the test animal should be assessed on their own merits.

Communicating Adverse and NOAEL

- Recommendation 5: Communication of what is considered adverse and assignment of the NOAEL in the overall study report should be consistent with, and supported by, the information provided in the study sub-reports.
- Recommendation 6: Communication of adverse findings and the NOAEL should include direct interaction between staff within different contributing scientific disciplines.
- Recommendation 7: The NOAEL for a test article should be communicated in an overview document based upon data from multiple studies.
- Recommendation 8: In order to place them in appropriate context, the use of NOAELs in data tables should be referenced to explanatory text.

Using Adverse and NOAEL in Assessing Potential Human Risk

- Recommendation 9: Nonclinical scientists, including toxicologists, pathologists, and other contributing subject matter experts who interpret data from nonclinical studies, should be active participants in assessing and communicating human risk.
- Recommendation 10: All available data from all nonclinical studies must be evaluated together to define any potential toxicities and to predict human risk.

The ESTP-led effort focused on preparation for and holding a workshop of international experts to address ‘Adversity’ topics. This workshop yielded synergistic, complimentary and overlapping outputs to that of the STP Adversity working group (Palazzi et al. 2016). The international group of expert pathologists and toxicologists emphasized that a holistic, weight-of-evidence, case-specific approach should be followed for each adversity assessment. Similar to the STP output, the ESTP developed a tiered approach to hazard and risk assessment (Burhardt et al. 2015). It was recommended that non-clinical adversity should typically be determined at a morphological level (most often the organ) in the pathology report and should refer specifically to the test species. Final adversity calls, integration of target pharmacology/pathway information, and consideration of human translation should generally be made in the toxicology overview.

The ESTP group defined ‘Adverse’ as follows: “In the context of a nonclinical toxicity study, an adverse effect is a test item-related change in the morphology, physiology, growth, development, reproduction or life span of the animal model that likely results in an impairment of functional capacity to maintain homeostasis and/or an impairment of the capacity to respond to an additional challenge.”

Speaker Abstracts

In both recognizing the challenge of applying this definition to a binary outcome of a finding being either adverse or non-adverse, they specifically addressed the practical application of assigning adversity in the following contexts (Palazzi, et al. 2016):

Primary features of adversity (“Determinants”):

1. Pathological nature of effect
2. Lesion severity
3. Effect constellation

Further characterization of adversity (“Characteristics”):

- Exacerbation of spontaneous/background findings
- Direct versus indirect effects
- Adaptive responses
- Reversibility
- Extrapolation of longer-term or higher exposure
- Translatability/human relevance
- Mode Of Action (MOA) - Expected/exaggerated pharmacology

Using different approaches, both STP and ESTP outputs focused on restricting adversity determination and setting the study NOAEL to the test article’s specific effects and impact on the animals in the study. The adversity determination and NOAEL must be justified based on the data and scientific judgment, and then communicated appropriately.

While determination of adversity must not be accentuated or diminished based on extrapolation to other species (including both other laboratory animal species and humans), studies of longer duration, disease models or conditions, it is critically important for scientists (especially toxicologic pathologists) to communicate the impact beyond the current study. The recommendations of the STP and ESTP reinforce this need. Study scientists need to provide their competent professional judgment to communicate understanding of these extrapolations using knowledge of pathology, toxicology, and comparative medicine. Nonclinical scientists, especially toxicologic pathologists, are uniquely poised to partner with clinical and regulatory colleagues to ensure all information is adequately understood and communicated in a manner that allows drugs to be developed and substances to be used while protecting the safety of humans, animals and environment.

If done well, determinations and communication of adversity will provide regulators and physicians the knowledge and understanding needed to make well supported decisions that protect the health and well-being of humans and animals.

Speaker Abstracts

References:

Burkhardt, J., et al. (2015). The Study Pathologist's Decision-Making Process for Evaluating “Adversity” Results from the 4th ESTP International Expert Workshop in Paris, June 8 – 9, 2015. Poster

Dorato, M., and Engelhardt, J. (2005). The no-observed-adverse-effect- level in drug safety evaluations: Use, issues, and definition(s). *Regul Toxicologic Pharmacol* 42, 265–74.

Keller, D., et al. (2012). Identification and characterization of adverse effects in 21st century toxicology. *Toxicol Sci* 126, 291–97.

Kerlin, R., et al., (2016). Scientific and Regulatory Policy Committee: Recommended (“Best”) Practices for Determining, Communicating, and Using Adverse Effect Data from Nonclinical Studies. *Toxicol Pathol* February 2016 44: 147-162.

Lewis, R., et al. (2002). Recognition of adverse and nonadverse effects in toxicity studies. *Toxicol Pathol* 30, 66–74.

Palazzi, X., et al. (2016). Characterizing “Adversity” of Pathology Findings in Nonclinical Toxicity Studies: Results from the 4th ESTP International Expert Workshop. *Toxicologic Pathology* (In Press)



*Speaker Abstracts***So2: Nose - Larynx - Lung: Methods - Findings - Assessment*****Rosenbruch Martin***

*Bayer Pharmaceuticals Division, Early Development TOX-P&CP,
Wuppertal (Germany)*



Induced morphological findings of the respiratory tract occur predominantly due to inhalational exposure to various test items. Other methods of test substance application directly to the respiratory tract are intranasal or oro-pharyngeal application and intratracheal instillation.

To exactly evaluate and assess respiratory tract lesions one or even the most important prerequisite is an adequate and reproducible technical procedure, from necropsy to the final slide (e.g. fixation, trimming, cutting, staining).

During evaluation, "real" substance induced lesions have to be distinguished from artifacts, spontaneous and handling derived findings.

In the nose, depending on the characteristics of the test compound several different lesions may occur (Harkema et al. 2006), ranging from e.g. minimal cellular disorganization of the epithelium to inflammatory effects as well as metaplasia, hyperplasia or tumors.

The laryngeal epithelium, especially in rodent inhalation toxicity studies with particles, is a very sensitive tissue quite often determining the NOAEL. Therefore, "Larynx Squamous Metaplasia" during the 1st ESTP Expert Workshop some years ago was reconsidered and clear recommendations were given concerning the interpretation of laryngeal findings (Kaufmann et al. 2009).

Following test item exposure, the lung reacts with many different morphological effects, occurring in the airways, alveoli, blood vessels, interstitium or pleura.

The first morphological effect following inhalational exposure frequently is an increase of alveolar macrophages in number and/or size which - in the absence of other lesions - is regarded to be non-adverse (Nikula et al. 2014).

In conclusion, for the evaluation of induced morphological findings of the respiratory tract and their adversity high quality histotechnique is essential.

Assessing test item induced effects, findings representing normal organ functionality have to be distinguished from "real" adverse effects.

Speaker Abstracts

References:

Harkema, J.R., S.A. Carey, and J.G. Wagner (2006). The nose revisited: A brief review of comparative structure, function, and toxicologic pathology of the nasal epithelium. *Tox. Pathol.* 34, 252-269.

Kaufmann, W., R. Bader, H. Ernst, T. Harada, J. Hardisty, B. Kittel, A. Kolling, M. Pino, R. Renne, S. Rittinghausen, A. Schulte, T. Wöhrmann, and M. Rosenbruch (2009). 1st International ESTP Expert Workshop: “Larynx squamous metaplasia”: A re-consideration of morphology and diagnostic approaches in rodent studies and its relevance for human risk assessment. *Exp.Tox. Pathol.* 61, 591-603.

Nikula, K.J., J.E. McCartney, T. McGovern, G.K. Miller, M. Odin, M.V. Pino, and M.D. Reed (2014). STP Position Paper: Interpreting the significance of increased alveolar macrophages in rodents following inhalation of pharmaceutical materials. *Tox. Pathol.* 42, 472-486.



*Speaker Abstracts***S03: Non-neoplastic Lung Changes in Toxicological Studies and Adverse Definition****Piaia Alessandro***Novartis Pharma AG – NiBR – Preclinical Safety Project Pathology –Basel, Switzerland*

The respiratory system is one of the interfaces between an organism and the environment. It can represent the portal of entry into the body for infectious agents, inhaled pollutants or volatile substances, and it has been used as an entry for xenobiotics. In addition, the lung receives the whole output from the right side of the heart, therefore it can also receive any of the aforementioned substances/agents from this route. For these reasons, the lung is routinely examined in both non-inhalation and inhalation toxicology studies and a variety of lesions can be associated with administration of compounds by both routes.

Due to its complex architecture, lung lesions heavily depend not only on the toxicant, but also on the type of tissue affected. For example, bronchiolar airways are lined by a mixture of ciliated, mucous and basal cells, the former being more sensitive to toxicants than the latter two. One of the first responses that can be seen in the airways is degeneration with/without regeneration, characterized by the loss of cilia, rounding up of cells in a more cuboidal epithelium (Degeneration), pyknosis/karyorrhexis of nuclei (Necrosis) or more prominent basophilic cytoplasm with an increased nuclear/cytoplasmic ratio (Regeneration). The regenerative responses can progress into proliferative changes of the epithelium, which can be characterized by either a mixture of original cells (Hyperplasia, respiratory epithelium) or dominated by mucous cells (Hyperplasia, mucous cell). In short term studies, the hyperplasia is often mainly characterized by an increased height of cells, rather than a corrugated to papillated epithelium and it is usually reversible. Each finding can be interpreted as adverse or non-adverse, according to the distribution, severity and nature of the change. Important although not immediately assessable, is the time-relationship of changes: the lack of evolution of a change from short- to mid- or long-term studies may confirm the non-adverse adaptive nature of a finding. This especially applies for the alveolar bronchiolar junction in the rodent, where hyperplasia can be seen (Hyperplasia, bronchiolo-alveolar), initially developing to increase the lung clearance for particulate burden and able, over time, to be set as new stable condition with no further progression, as well as to develop into more severe lesions, including neoplastic evolution.

Inflammatory changes (Inflammation) can occur in both the airways, their termination and/or in the alveolar bed. Inflammation is usually considered detrimental to the resident cell populations and/or the lung function, and therefore adverse, despite the inflammatory cell population involved or other associated changes in the tissue (e.g. Necrosis, Edema etc). Insoluble materials (Pigments, dusts, inert materials) are known to be associated with inflammatory changes, and some substances (e.g. silica, titanium dioxide) can be used to dissect different molecular pathways associated with the ability of those substances to evoke different tissue reactions.

Following the international harmonization of nomenclature and diagnostic criteria (INHAND) for respiratory tract lesions in laboratory animals, the presentation will demonstrate examples of changes that can be observed in the lung and discuss whether or not they can represent an adverse finding.

Speaker Abstracts

References:

Plopper C.G. (1996) In: Monographs on Pathology of Laboratory Animals – Respiratory system, Structure and function of lung. 2nd Ed. Eds Jones T.C., Dungworth D.L. Mohr U. (Springer Verlag Berlin) pp135-149

Renne R. et al. (2009). Proliferative and Nonproliferative Lesions of the Rat and Mouse Respiratory Tract. Toxicol Pathol 37: 5S-73S.



*Speaker Abstracts***So4: Translational pathology of lung toxicity****Moulin Pierre**

Novartis Pharma AG – NiBR – Preclinical Safety – Discovery and Investigative Pathology – Basel, Switzerland



Drug-induced lung disease (DILD) is rare in the common population but can reach 10% of incidence in specific patient groups such as those oncology patients treated with several lines of chemotherapy. Many drugs can produce pulmonary adverse events, and their manifestations span the entire spectrum of clinic-pathological entities of the respiratory tract: from bronchospasm to interstitial infiltrative lesions or mimic a vascular disease.

Even though all types of presentation are of equal importance, the interstitial lung disease caused by drugs has a particular prognostic and pathologic significance as it ranges from benign infiltrates to life-threatening acute respiratory distress syndrome.

DILD is not associated with any particular clinical presentation. The diagnosis of DILD is difficult and based on exclusion of primary or secondary lung diseases including infections and other systemic or lung-specific diseases.

Identification of the causative drug necessitates the integration of the clinical history with the information gathered during the workup. The identification of the causative drug is addressed through specific criteria: Temporal relationship with exposure including a possible latent period; characteristic reaction pattern (if already documented); remission of the symptoms upon drug withdrawal; recurrence with re-challenge (ideal but not frequently performed); differentiation from the other drugs the patient is taking.

Depending on the clinical syndrome, the workup of DILD will comprise functional test, high resolution CT, bronchiolo-alveolar lavage (BAL), endobronchial or open-air biopsy.

The histopathology of DILD is variable. It can present a pattern of acute lung injury such as diffuse alveolar damage, or bronchiolitis obliterans organizing pneumonia. It can also take the form of any of the interstitial pneumonias: usual interstitial pneumonia, desquamative interstitial pneumonia, chronic non-specific interstitial pneumonia or other forms of pulmonary lesions such as eosinophilic pneumonia, hypersensitivity pneumonia or pulmonary alveolar proteinosis.

BAL is useful on the workup of pulmonary toxicity. It provides complimentary information to biopsies. It provides information on almost an entire segment of the lung, which is advantageous to assess the inflammatory or immunological components of DILD.

Moreover, it can be used more repeatedly than biopsies and allows investigate the temporal progression of pathological changes.

The mechanisms of DILD are difficult to identify. It seems however that they can be separated into two categories: direct, dose-dependent toxicity, and immune-mediated reaction. Cytotoxic drugs cause lung toxicity through direct injury of pneumocytes or the alveolar capillary endothelium. Most immunological reactions to drugs are of delayed type and involve T cells. In this context, assessment of

Speaker Abstracts

the presence or absence of drug-sensitized lymphocytes could play a role in the diagnosis of drug-induced disease.

The relatively low incidence of DILD makes its difficult to study from a mechanistic point of view, and both its forward and reverse translational aspects are complex.

The challenges in forward translation relate to the understanding of adversity of the preclinical findings based on their mechanisms or the ability to monitor them.

The reverse translation necessary to model the pathogenesis of DILD in animals, is made difficult by the complex histological presentation combined with the individual variation in drug metabolism. The ability to adequately translate findings between animals and humans also depends on the putative mechanism of toxicity. The direct cytotoxicity being probably easier to detect and reproduce preclinical than the immunological mechanisms.

References:

Camus, P., Bonniaud, P., Fanton, A., Camus, C., et al. (2004) Drug-induced and iatrogenic infiltrative lung disease. *Clinics in chest medicine*. [Online] 25 (3), 479–519–vi. Available from: doi:10.1016/j.ccm.2004.05.006.

Flieder, D.B. & Travis, W.D. (2004) Pathologic characteristics of drug-induced lung disease. *Clinics in chest medicine*. [Online] 25 (1), 37–45. Available from: doi:10.1016/S0272-5231(03)00138-2.

Matsuno, O. (2012) Drug-induced interstitial lung disease: mechanisms and best diagnostic approaches. *Respiratory Research*. [Online] 13 (1), 39. Available from: doi:10.1186/1465-9921-13-39.

Schwaiblmair, M., Behr, W., Haeckel, T., Märkl, B., et al. (2012) Drug Induced Interstitial Lung Disease. *The Open Respiratory Medicine Journal*. [Online] 6 (1), 63–74. Available from: doi:10.2174/1874306401206010063.

*Speaker Abstracts***S05: Digital Pathology Solutions for Preclinical Assessment****Schumacher Vanessa¹, Benmansour Fethallah²***¹Pathology, Pharmaceutical Sciences and ²pRED Informatics, in Pharma Research and Early Development, Roche Innovation Center Basel*

Digital pathology offers great potential drive preclinical research, allowing scientists to acquire, objectively quantify, and quality control data from tissue-based assessments. In this way, digital pathology is complementary to other large Omics data (proteomics, genomics, transcriptomics, etc) while providing a morphological context. Slides can be multiplexed in silico and reconstructed into 3D images. Additionally, this field offers opportunity to annotate and share slides, helping colleagues to collaborate easier than ever before.

This talk will focus on describing a flexible imaging workflow for tissue-based analysis in the preclinical setting, from bright-field and fluorescent whole-slide digital images. Illustrative examples will include characterization of compound distribution in tissue, in silico multiplexing of serial tissue sections and immune cell characterization of a humanized mouse model.

Key components of a good imaging workflow include establishing scientifically driven, observable endpoints to be measured, deciding on the right image analysis tools for the job, opportunities for quality control, and the ability to clearly communicate results in an easily interpretable manner. Successful digital pathology workflows begin long before an image is acquired, during the study design and tissue preparation phase. Knowledge of the information “going in” to the analysis is essential to allow for interpretation and quality control of results.

Speaker Abstracts

So6: Digital pathology in GLP environment

Klapwijk Jan and Barale Erio



*Speaker Abstracts***S07: Comparative Pathophysiology of the Thyroid Gland: Human Relevance in Preclinical Toxicity Studies****Rosol Thomas J., DVM, PhD***The Ohio State University, Columbus, Ohio, USA*

The thyroid gland is an evolutionarily conserved endocrine organ that is present in all vertebrates including primitive fishes and all animals including mammals and humans. The gland produces two principal hormones, namely thyroxine (T₄) and triiodothyronine (T₃), which contain 4 and 3 iodine atoms, respectively. The basic structure of the thyroid gland and the T₄ and T₃ hormones are identical in all vertebrates. The thyroid gland is composed of follicles lined by a single layer of thyroid follicular cells that may be flattened (squamous) to columnar depending on the cellular activity of the follicle. The follicles contain protein-rich fluid colloid that represents thyroglobulin and bound precursor hormones. All follicles are not necessarily in the same physiologic state and may vary in activity. Inactive follicles contain abundant colloid and flattened epithelium. Follicles that are actively synthesizing and secreting thyroid hormones have reduced colloid and cuboidal to columnar follicular epithelial cells. Vacuoles may be present in the colloid that is adjacent to the follicular epithelium. The vacuoles are not present in vivo and are thought to be a fixation artifact; however, it appears that the number of vacuoles is increased in active follicles.

The cell membrane of the basal aspect of the thyroid follicular cells contains the sodium iodide symporter (NIS) that is responsible for transporting iodide (I⁻) against a concentration gradient, which is necessary for thyroid hormone synthesis. NIS is dependent on ATP and a Na-K ATPase to provide the energy for iodide transport.

Thyroid stimulating hormone (TSH) from the pituitary gland is the principle hormonal regulator of iodide uptake, thyroid hormone synthesis and secretion, and thyroid follicular cell proliferation. However, other endocrine hormones, paracrine hormones, C cells, and nerve cells also regulate thyroid follicular cell function.

There are many conditions and chemicals that disrupt normal thyroid hormone synthesis, secretion, action, or metabolism by multiple mechanisms. This makes it challenging to identify modes of action (MOA) of chemicals that alter thyroid hormone economy. Potential mechanisms include reduced thyrotropin production by the hypothalamus or TSH by the pituitary thyrocytes and inhibition of iodide uptake by thyroid follicular cells; thyroglobulin synthesis; thyroid peroxidase (necessary for organization of iodide); thyroid hormone release from thyroglobulin; thyroid hormone secretion; thyroid hormone binding to serum proteins; thyroid hormone transport into cells; binding of T₃ to thyroid hormone receptors, and deiodination of T₄ to T₃. T₄ is actually a prohormone and the biologically active thyroid hormone is T₃. T₄ can be deiodinated to T₃ in the thyroid gland, liver, or end organs by three different deiodinases. In addition, activation of phase II enzymes in the liver (such as UDP-glucuronosyltransferase or sulfotransferase) can increase metabolism and excretion of T₄ (especially in rats).

There are important differences between species (rodents, dogs, pigs, and primates) in the regulation of thyroid hormone production, metabolism, half-life, and action. Therefore, chemicals that disrupt thyroid hormone economy in one species, such as the rat, may not have significant effects in other

Speaker Abstracts

species, such as the dog or human. One important difference is the presence of thyroid binding globulin (TGB) in the blood. TBG is a T₄ high-affinity binding globulin that prolongs the half-life of T₄ and is present in dogs and primates, but is not in rodents. Therefore, the serum half-life of T₄ is significantly longer in humans (7 days) compared to rodents (24 hours). Rats have greater TSH concentrations and T₄ synthesis (per body mass) compared to humans and dogs.

There are also important differences in genetic susceptibility to preneoplastic conditions (focal thyroid follicular hyperplasia) and neoplasia of thyroid follicular cells in animals (mice, rats, dogs, subhuman primates) compared to humans. The histologic pattern and progression of thyroid follicular tumors varies by species. For example, papillary thyroid tumors are the most common tumor type in humans, but are rare in animals.

The role of TSH as a promoter of thyroid follicular tumors is clear in rats, but is controversial in humans. It does not appear that TSH is a thyroid follicular promoter in humans; however, humans with thyroid cancer tend to have modest increases in serum TSH concentrations.

Chemicals that disrupt thyroid hormone economy and result in increased serum concentrations of TSH often induce benign and malignant thyroid follicular tumors in rats and mice in 2-year carcinogenicity studies. Determination of the mode of action and prediction of human relevance is necessary for regulatory review. The approach for mechanistic endocrine studies in animals and potential human relevance will be discussed.

References:

Chandra, S, Hoenerhoff, MJ, and Peterson, R. Endocrine System (2013). In: Toxicologic Pathology: Nonclinical Safety Assessment. Sahota, PS, Popp, JA, Hardisty, JF and Gopinath, G (eds). CRC Press, Boca Raton, FL. pp. 655-716.

Rosol TJ, DeLellis RA, Harvey PW, Sutcliffe C. Endocrine System (2013). In: Haschek, W.M., Rousseaux, C.G., Wallig, M.A. (Eds.), Haschek and Rousseaux's Handbook of Toxicologic Pathology. Elsevier Inc., Academic Press, pp. 2391–2492.

*Speaker Abstracts***So8: Compound-induced thyroid gland effects in rats - evaluation of mechanism and potential relevance for humans – the theory****Freyberger Alexius***Bayer Pharma AG, 42113 Wuppertal, Germany*

Thyroid hormones (THs) play an important role in mammalian organisms regarding metabolism, calorogenesis, growth and development. Both hypo- as well as hyperthyroidism are associated with adverse effects. The synthesis of THs by the thyroid gland is regulated through a complex interplay of hypothalamus, pituitary gland and the thyroid. A concerted action of hypothalamic and pituitary hormones, TH-synthesizing and metabolizing enzymes, TH binding proteins and transporters and TH-mediated negative feedback mechanisms results in normal TH level in healthy individuals. It is well recognized that in the rat the homeostasis of THs is readily disturbed by a broad variety of compounds acting via different mechanisms. Mechanisms known for long include inhibition of the synthesis and deiodination of THs, increased metabolic disposition of THs through liver enzyme induction and displacement from TH binding proteins. Inhibition of TH transporters and of recycling of iodide from residual iodotyrosines seems to be emerging mechanisms. Examples for the different mechanisms will be given and their human relevance will be discussed.



*Speaker Abstracts***S09: Compound-induced thyroid gland effects in rats – Evaluation of mechanism and potential relevance for humans – the practice*****Bach Ute and Rinke Matthias****Bayer Pharma AG, 42113 Wuppertal, Germany*

Alterations in the morphology of the thyroid gland in rats are frequently considered as a species specific change with no toxicological relevance for humans due to a variety of pathways that differ among the species. After presentation of the theoretical background of possible thyroid effects, in this interactive presentation, examples from agrochemical/veterinary medical and pharmaceutical research and development are given to show the difficulties in identifying morphological differences and assessing the changes finally for their relevance for humans.

The first example is taken from a compound that first was developed as an agrochemical but then was considered to be useful also for veterinary practice. The compound was administered by gavage for 2 weeks to male and female Crl:WI (Han) rats. Food and water intake were in normal ranges. Necropsy revealed significantly increased absolute and relative liver weights (males up to 60%, females up to 90%), accompanied by enlargement and discoloration which corresponded histopathologically to a marked hepatocellular hypertrophy and periportal cytoplasmic change. In the thyroid gland, hypertrophy and beginning hyperplasia of the follicular cell epithelium was observed, which was characterized by increased epithelial cell height, rarefaction of the cytoplasm and occasional infoldings of the follicles. The follicular size was varying. In the pituitary gland of males, an increased number of pale cells were observed as well. In both genders hemoglobin was slightly decreased while the thrombocyte count was clearly increased. Gamma-GT and cholesterol values were markedly increased in females, and less pronounced in males. Determination of enzyme activities in the liver showed increased values for Epoxide hydrolase, Glutathione-S-transferase, and UDP-Glucuronyltransferase. These data suggest that the thyroidal findings are related to an increased clearance of thyroidal hormones in the liver. Has this effect to be regarded as adverse?

The second example is taken from a 4-week repeat-dose toxicity study in rats with a pharmaceutical compound in which during the course of the safety assessment unexpected findings in the thyroid and pituitary gland occurred. They were characterized by significant changes in thyroid hormone levels, which were associated by comparable morphological alterations in the thyroid gland as described for the first example. They were accompanied by changes in the pituitary gland but not in the liver. Mechanistic studies showed, that the compound inhibits directly the hormone synthesis in the thyroid gland, which leads to a hypothyroid metabolic status with the before mentioned effects. The possible relevance/adversity for the human situation has to be discussed.

References:

McClain, RM (1995): Mechanistic considerations for the relevance of animal data on thyroid neoplasia to human risk assessment. *Mutation Research*, 333, 131 – 142.

R N Hill, T M Crisp, P M Hurley, S L Rosenthal, and D V Singh (1998): Risk assessment of thyroid follicular cell tumors, *Environ Health Perspect* 106, 447–457.

*Speaker Abstracts***S10: Adverse effects in the thyroid gland: examples out of Crop Science**

Schorsch Frederic, DVM, MSc Tox Path, DESV Ana-Path, Dipl. ECVP
Bayer Crop Science, Sophia Antipolis, France



Different families of agrochemical compounds - with quite various chemical structures and different mode of actions - are known to affect the thyroid gland in different ways. For this presentation we will concentrate on three classes of compounds. Different morphological changes illustrating the reaction of the thyroid gland will be shown: colloid alteration, follicular cell proliferation, follicular cell hypertrophy/hyperplasia, adenomas and carcinomas. The relevance to humans of those changes will be discussed.

The first example concerns herbicides belonging to HPPDase inhibitors. HPPDase inhibitors are herbicides inhibiting the activity of 4-hydroxyphenyl-pyruvate dioxygenase (4-HPPDase), the enzyme which converts 4-hydroxyphenylpyruvic acid to homogentisic acid. In target plants, there is no formation of homogentisic acid, the precursor that leads to the biosynthesis of the plastoquinones and alpha-tocopherol required for the photosynthesis. Such compounds are known to increase tyrosine concentrations in blood of mammals. There are a lot of changes related to tyrosinemia such as colloid alteration in the thyroid gland and corneal inflammation in the rat. The relevance of this change in humans will be discussed due to a different catabolism pathway of tyrosine compared to the rat.

The second example, also an herbicide (sulfonylurea herbicide for use on cereals) will be a direct thyroid toxicant, representing a goitrogenic mode of action due to the release of excessive amount of iodine. The iodine released from the active ingredient was responsible for the thyroid effects detected in animal studies. Those effects will be presented. This compound has been stopped as it would induce the same reaction in human beings.

The third example will be Fluopyram, a broad spectrum pyridylethylamide fungicide. It controls fungi by inhibiting the enzyme succinate dehydrogenase, which is a functional part of the tricarboxylic acid cycle linked to mitochondrial electron transport. Fluopyram is known to be an indirect toxicant for the thyroid gland via the activation of Car and Pxr receptors. In carcinogenicity studies, fluopyram caused thyroid tumors in the male mouse. The MOA for the thyroid tumors includes the following key events: 1) activation of the Car/Pxr receptors and increased activity of detoxification enzymes, 2) increased thyroxine (T₄) thyroid hormone clearance, 3) increased levels of thyroid stimulating hormone (TSH), and 4) increased follicular cell hyperplasia that process to thyroid tumors. These key events will be presented in a series of MOA studies aimed at providing data to illustrate the indirect MOA (mode of action) on the thyroid gland known to be not relevant for humans.

*Speaker Abstracts***S11: Renal Tubule Hyperplasia in Rats****Hard Gordon***New-Zealand*

Increase in the number of epithelial cells lining the renal tubules of rats (renal tubule hyperplasia) can be of several types. As in the INHAND document, renal tubule hyperplasia can be simple, where the single cell layer of the tubule is retained, or atypical, where the increase in tubule cells is multi-layered or solid. A form of solid hyperplastic foci also occurs in end-stage chronic progressive nephropathy (CPN), probably representing an adaptive response in the failing kidney. Tubule hypertrophy does not involve an increase in cell number, but an increase in tubule cell size. Each of these types will be considered in this presentation.



*Speaker Abstracts***S12: Karyomegaly Versus Nuclear Enlargement****Hard Gordon***New-Zealand*

Nuclear enlargement (called karyomegaly in the INHAND document) in rodent kidney tubules can occur in a number of situations. Increase in nuclear size occurs as the dividing tubule cell passes through the cell cycle; can be present as a sporadic, long-term finding in chronic studies with some epigenetic carcinogens; occurs frequently and at an early stage after exposure to some mycotoxins; and can occur at a slower rate of onset in S3 tubules with a few compounds such as β -myrcene. Each of these types of nuclear enlargement will be illustrated, and discussed.



*Speaker Abstracts***S13: Adversity in the Kidney: Hyaline Droplets and Alpha-2u-globulin Nephropathy****Frazier Kendall***GSK, King of Prussia, PA, USA*

Most of the drug-induced toxic tubule lesions noted in kidney are considered adverse, based on deleterious functional effects on the nephron. However, one area where adversity may be in question is regarding hyaline droplets in rats. Hyaline droplets are frequently found in the cytoplasm of proximal tubules in male rats, generally localized to the S2 segment, and are characterized by variably sized, refractile, brightly eosinophilic ovoid droplets consisting of lysosomal accumulations of α -2U-globulin. There are a large number of agents (d-limonene, hydrocarbon or petroleum products, decalin) that will result in

α -2u-globulin nephropathy, characterized by an increase in droplet number and distribution, and/or altered pattern of droplet distribution. “Hyaline Droplet Nephropathy” is the preferred term to use as a morphologic diagnosis in a toxicity study when there is some question about the nature of the accumulated material making up the droplets, and α -2u-globulin nephropathy is the preferred term when lesions are confirmed to be related to that protein. This differentiation can be determined by use of special procedures such as Mallory Heidenhain, Martius scarlet blue, chromotrope-aniline-blue or immunohistochemical stains. Incidence limited to males, lack of evidence of degeneration, and characteristic morphology and location may all be helpful in the diagnosis without special stains. α -2u-globulin is a freely filtered, androgen-regulated protein synthesized in the liver of male rats, and is the major excreted urinary protein in this gender and species. The amount of protein in the diet can greatly influence tubular protein reabsorption and hence affect the incidence of the condition. The rate determining step in the development of drug-induced forms of α -2u-globulin nephropathy are reversible, non-covalent binding of the agent to the protein. While the binding site in rats forms a large cavity, in the homologous low molecular weight urinary proteins of other species such as mouse and human, the cavity is shallow and does not easily accommodate ligand binding. Therefore, α -2u-globulin nephropathy is considered a rat specific phenomenon, and clinical relevance may be negligible. There has been an association with increased incidence of proliferative lesions (hyperplasia, adenomas and carcinomas) in the kidneys of rats with hyaline droplets in two year bioassays, but this does not necessarily imply carcinogenic potential in humans, as the rodent specific mechanism is considered related to a compensatory increase in proliferation and cell turnover. While many drugs typically result in an increase in α -2U-globulin accumulation, some xenobiotic agents may result in accumulation of hyaline droplets within secondary lysosomes of proximal tubules in rats that consist of other low-molecular-weight proteins, or of drug-protein complexes. Prominent eosinophilic droplets also occur in the cytoplasm of proximal tubules in rats with systemic histiocytic sarcoma, and are composed of lysozyme. While there is no clinical relevance of histiocytic sarcoma droplets, drug-induced lysosomal complexes of other types may occur in human kidneys as well as in rats. A case example of hyaline droplets will be presented for discussion of diagnosis, adversity and clinical implications.

*Speaker Abstracts***S14: Adversity in the Kidney:
Glomerulonephritis and Glomerulopathies****Frazier Kendall***GSK, King of Prussia, PA, USA*

Glomerulonephritis has been noted recently with increasing frequency with the growing prevalence of biopharmaceuticals and complex macromolecules in active drug development. Antibody- or complement- mediated injury is a frequent, but not essential component of glomerular toxicity, and immune complex disease has been related to many cases of drug-induced glomerular injury. While virtually all glomerular lesions are considered adverse, it can often be very difficult to determine whether a glomerular lesion noted in a toxicity study is drug-related, due to the idiosyncratic nature and incidence. The concurrent presence of anti-drug antibodies (ADA) may be very helpful, as well as ancillary procedures to assess the nature and character of the lesions, such as immunofluorescence for immune complexes and complement fractions, localization of the drug at the site of injury, and electron microscopy to assess ultrastructure. ADAs form relatively often in monkeys because recombinant human proteins are sufficiently different from homologous monkey proteins to result in immunogenicity. Large complexes or drug aggregates may be formed from an administered drug itself and result in immune reactions in the glomerulus, even without the participation of ADA, and there are also a few clinical cases where immunomodulatory biologics have induced glomerulonephritis as part of a systemic vasculitis through widespread cytokine activation. Periodic acid-Schiff (PAS) stains, silver stains or specific immunohistochemical stains may be utilized to better delineate the cellular components of the glomerulus. In all of its manifestations, glomerulonephritis is characterized by cellular proliferation. Glomerulonephritis can be divided into membranous/membranoproliferative and crescentic forms in rodents, dogs and monkeys. Differences between membranous and membranoproliferative forms in laboratory animals are not as pronounced as in humans and the distinction is not particularly informative. Glomerulonephritis is associated with inflammatory cytokine involvement and potential complement activation within the glomerular capillaries. In contrast, a distinct drug-induced entity- mesangioproliferative glomerulopathy- lacks significant capillary involvement or inflammation, and primarily involves damage to the mesangium. Other types of glomerular injury include hyaline glomerulopathy and amyloidosis in mice, mesangial proliferation, mesangiolysis, glomerular atrophy, dilation of Bowman's space and metaplasia of Bowman's capsule. A case example of glomerular injury in a monkey will be presented for discussion of diagnosis, adversity and clinical implications.

*Speaker Abstracts***S15: Renal findings in a Cynomolgus monkey toxicity study with an oncology compound. Highest Non-Severely Toxic Dose (HNSTD), relevance for humans and benefit-risk ratio.**

Laurent Sébastien, Chanut Franck, Herbet Aurélie, Gallas Jean-François

Sanofi, Preclinical Safety, 371, avenue du Professeur Blayac, 34184 Montpellier, France



Hepatocellular carcinoma (HCC) is a leading cause of cancer-related death. Patients with HCC frequently present with tumors at advanced and incurable stages, and are ineligible for surgical resection or other forms of treatment with curative potential. Currently, only poorly effective treatment options are available for those patients, and the need for better therapies is evident.

The Fibroblast Growth Factor (FGF) 19 - Fibroblast Growth Factor Receptor (FGFR) 4 signaling pathway has emerged as a potential key driver in some forms of HCCs, making it a promising molecular target for therapeutic intervention.

In a repeat-dose preclinical toxicity study conducted in the Cynomolgus monkey with an FGFR₄ tyrosine kinase inhibitor, renal histopathological findings of mineralization of the papilla and medulla, together with tubular degeneration/regeneration and dilatation were observed. These changes were associated with an elevation of the blood phosphorus levels.

In this interactive session, the relevant aspects of the biology of the FGF family, as well as the compound-induced renal lesions and associated changes in clinical pathology that were observed in the study will be presented. Subsequently, the mechanism of side effects and their relevance for humans, the determination of the HNSTD under the conditions of the study, as well as the assessment of the benefit-risk ratio in the context of the indication (i.e. severe and life-threatening malignancy) will be discussed with the audience.

References:

Gattineni J et al. (2014) Regulation of renal phosphate transport by FGF23 is mediated by FGFR1 and FGFR4. *Am J Physiol Renal Physiol.* 306 (3): F351-F358.

Mellor HR (2014) Targeted inhibition of the FGF19-FGFR4 pathway in hepatocellular carcinoma; translational safety considerations. *Liver Int.* 34 (6): e1-9.

Repana D and Ross P (2015) Targeting FGF19/FGFR4 pathway: a novel therapeutic strategy for hepatocellular carcinoma. *Diseases.* 3 (4): 294-305.

*Speaker Abstracts***S16: Adverse or not adverse: Treatment-related findings in renal distal tubules and collecting ducts in Wistar rats****Rinke Matthias and Bach Ute***Bayer Pharma AG, 42113 Wuppertal, Germany***Introduction:**

Renal toxicity represents a frequent observation in pre-clinical toxicity studies. However, mostly alterations of the proximal tubules and/or the glomeruli are causing a problem. In this interactive presentation, we will provide an example of treatment-related hypertrophy with some degenerative features of the distal renal tubules and somewhat proliferative changes within the collecting duct epithelium of the papilla in kidneys seen in male and female Wistar rats. An attempt is made to find an explanation for the mechanism behind the lesions and the relevance of these rat findings will be discussed in the context adversity and of their human relevance.

Material and Methods:

Male and female Wistar rats (Hsd Cpb:WU) were used for the experiments and were treated orally with a pharmaceutical compound X. In the course of the evaluations, it turned out that females were less susceptible to the lesions and thus were dosed differently. A complete histopathological evaluation according to the guidelines was performed, whereas in case of mechanistic studies, a limited panel of organs was investigated. Mainly diagnosis was done on Davidson's fixed, H&E sections, but special stains were performed exemplarily.

Results:

All discussions began with a 4-week gavage study, in which the cortical distal tubules showed signs of slight to moderate hypertrophy of their epithelial cells in all males of the high dose group and comparable, minimal to slight findings in 6/10 females. Had this finding to be considered as adverse?

In the following 13-week gavage study using the same dosages, renal weights were increased in the high dose group. Urinary volume was increased and protein, urea and creatinine concentration in the urine were decreased. Clinical chemistry revealed an increase in plasma urea. Hypertrophy of the distal tubular epithelium had expanded and was found now in the cortex and medulla. These epithelial cells revealed additionally some signs of hyperplasia. As a new finding, hyperplasia of the collecting ducts was observed which was characterized by the formation of epithelial buds, partly with intraluminal sloughing of epithelial cells. Occasionally, the finding was accompanied by degenerative changes and increased interstitial mononuclear cell infiltration.

Urinary volume was increased and protein, urea and creatinine concentration in the urine were decreased. Clinical chemistry revealed an increase in plasma urea. Are these conditions to be considered as adverse?

Speaker Abstracts

The 26-week study was performed using a third of the formerly administered dosage for the high dose animals. Only a few male rats showed a minimal hyperplasia of the papillary collecting ducts. No findings were observed in the distal tubules of either sex. Thus, would the finding to be considered as adverse?

Conclusions:

To maintain the eagerness and excitement, the conclusions will be elaborated during the presentation, in which the possible mode of action will be discussed.



*Speaker Abstracts***S17: Translation Pathology of Kidney Toxicity****Moulin Pierre**

Novartis Pharma AG – NiBR – Preclinical Safety – Discovery and Investigative Pathology – Basel, Switzerland



Drug induced kidney injury (DIKI) is a frequent cause of acute renal injury. Most of the cases of DIKI appear as acute interstitial nephritis (AIN). Similarly, drug induced disease represents the the most common cause of AIN with 2/3 of the cases. Aside from tubulointerstitial disease, drug-related glomerular injury is far less well appreciated. However, it may be of high clinical importance.

Acute interstitial nephritis (AIN), is a common cause of acute kidney injury, and is caused primarily by drugs, but also infections, autoimmune diseases, systemic inflammation, and there are also idiopathic forms. It should be suspected in front of any unexplained progressive rise in serum creatinine.

The clinical presentation of toxic AIN may be different from one causative drug to another. The classical symptoms are nonspecific (malaise, anorexia, chills, abdominal or flank pain, arthro-myalgia). If a hypersensitivity syndrome (fever, rash, eosinophilia) is associated with the clinical presentation, it orients the diagnosis towards a DIKI form of AIN.

Because the diagnosis is sometimes ambiguous, renal biopsy is an integral part of the workup. The histological findings in AIN consist in interstitial inflammation, oedema, and the presence on immune cells in-between tubular epithelial cells (tubulitis).

DIKI can also present as a glomerular syndrome. Glomerular toxicity can be caused by direct injury of the cellular components of the glomerulus (mesangium, endothelium, or podocytes), or by immune-mediated injury.

The glomerulopathies caused by direct cellular injury comprise nodular glomerulosclerosis (mesangial cell), thrombotic microangiopathy (endothelial cell), and minimal change disease or focal and segmental glomerulosclerosis (FSGS - podocyte). The drugs that cause such lesions are interferons, bisphosphonates, nonsteroidal anti-inflammatory drugs, antiplatelet agents, and antiangiogenesis drugs.

Immune-mediated glomerulopathies are related to the production of antibodies, or activation of auto-reactive T lymphocytes. Through these mechanisms, drug may mimick lupus (procainamide, hydralazine, TNFalpha inhibitors), membranous nephropathy (gold, penicillin, captopril), or ANCA-associated vasculitides (cocaine, propylthiouracil, sulfasalazine).

Speaker Abstracts

References:

Hogan, J.J., Markowitz, G.S. & Radhakrishnan, J. (2015) Drug-Induced Glomerular Disease: Immune-Mediated Injury. *Clinical Journal of the American Society of Nephrology*. [Online] 10 (7), 1300–1310. Available from: doi:10.2215/CJN.01910215.

Markowitz, G.S., Bomback, A.S. & Perazella, M.A. (2015) Drug-Induced Glomerular Disease: Direct Cellular Injury. *Clinical Journal of the American Society of Nephrology*. [Online] 10 (7), 1291–1299. Available from: doi:10.2215/CJN.00860115.

Perazella, M.A. & Markowitz, G.S. (2010) Drug-induced acute interstitial nephritis. *Nature reviews. Nephrology*. [Online] 6 (8), 461–470. Available from: doi:10.1038/nrneph.2010.71.

Radhakrishnan, J. & Perazella, M.A. (2015) Drug-Induced Glomerular Disease: Attention Required! *Clinical Journal of the American Society of Nephrology*. [Online] 10 (7), 1287–1290. Available from: doi:10.2215/CJN.01010115.



*Speaker Abstracts***S18: Comparison of investigative imaging techniques in drug-induced crystal nephropathy****Lenz Barbara, de Paepe Anne and Brink Andreas***Roche Pharmaceutical Research & Early Development, Pharmaceutical Sciences and Therapeutic Modalities, Roche Innovation Center Basel*

A number of drugs are known to cause precipitates within renal tubules leading to intratubular obstruction and acute kidney injury termed “crystal nephropathy”. Precipitates are primarily due to oversaturation of urine or drug insolubility at alkaline or acid urine pH. Crystal nephropathy is usually an exposure-related finding and is not uncommon in preclinical studies where high doses of compounds are tested. A good understanding of the nature of precipitates is important for human risk assessment and further development. Various imaging techniques to determine presence of drugs or metabolites in tissue sections are nowadays available and they are also receiving more attention in preclinical safety studies. This talk is focusing on MALDI mass spectrometry imaging, Raman or infrared microspectroscopy and scanning electron microscopy coupled with energy dispersive X-ray (SEM/EDX) spectroscopy. These techniques were applied to cases of crystal nephropathies induced by four molecules in rodent and non-rodent animals with varying chemical structures and pharmacological activities. The results of these investigations will be presented, advantages and disadvantages of the individual technique will be discussed and a workflow for further characterization of crystal nephropathies will be suggested.

References:

Yarlagadda, S.G., Perazella, M.A, (2008). Drug-induced crystal nephropathy: an update. *Expert Opin. Drug Saf.* 7, 147–158.

Groseclose, M.R., Laffan S.B., Frazier, K.S., Hughes-Earle, A., Castellino, S, Imaging MS (2015) in *Toxicology: An Investigation of Juvenile Rat Nephrotoxicity Associated with Dabrafenib Administration*. *J. Am. Soc. Mass Spectrom.* 26, 887-898.

*Speaker Abstracts***S19: Kidney pathology, evaluation of cisplatin-induced proximal tubular injury in Cynomolgus monkeys using laser ablation inductively coupled plasma-mass spectrometry**

Van Heerden Marjolein¹, Van Acker Thibaut², Van Malderen Stijn², McDuffie James Eric³, Cuyckens Filip¹ and Vanhaecke Frank²

¹Preclinical Development and Safety, Janssen R&D, Beerse, Belgium, ²Department of Analytical Chemistry, Ghent University, Belgium, ³Preclinical Development and Safety, Janssen R&D, San Diego, USA



A 4-day cisplatin nephrotoxicity study in male and female Cynomolgus monkeys was designed to evaluate biomarkers associated with minimal cisplatin-induced renal lesions. At histology minimal to mild cisplatin-related lesions (< 100 µm) were observed in the renal cortex and outer stripe of outer medulla (OSOM). Two-dimensional elemental mapping (bioimaging) via laser ablation-inductively coupled plasma-mass spectrometry (LA ICP MS) was performed on 5 µm thick formalin-fixed, paraffin embedded kidney tissue sections from female Cynomolgus monkeys administered with increasing pharmacological doses of cisplatin. A lateral resolution down to 1 µm was achieved, enabling elemental analysis on a (sub)cellular level. Necrotic proximal tubules with sloughed epithelial cells in their lumen could be linked directly to the areas with the highest accumulation of cisplatin, indicating a direct link between cellular concentration and toxicity. This study illustrated the capabilities of LA-ICP-MS to perform high-resolution mapping of the distribution of this metal-containing drug on a cellular level, by localizing cisplatin in representative formalin-fixed, paraffin-embedded kidneys from Cynomolgus monkeys with cisplatin-induced proximal tubular lesions.

*Speaker Abstracts***S20: Adverse and non adverse changes in the lymphoid system****Pearse Gail, Director Pathology**

GSK, Translational Medicine & Comparative Pathobiology, Park Road, Ware, Hertfordshire, SG12 0DP, United Kingdom



In recent years there has been a surge in the publication of the guidance for nonclinical study pathologists in determining, communicating, and using adverse effect data. (ESTP International Expert Workshop (2015) and Kerlin et al. *Toxicol Pathol* 2016 44: 147). However, the distinction between an adverse and non-adverse change associated with chemical exposure often remains the most discussed and difficult decision we face. In the case of the immune system this is compounded by the complexity of immunological mechanisms. Physiological influences such as age, stress levels, diet, and background infection can have a profound effect on the immune system of the test species. The existence of functional redundancy and compensatory mechanisms means histopathology and clinical hematology may remain within normal range despite exposure to an immunosuppressant. The immunomodulatory drugs under development are designed to rebalance the disrupted immune system of patients but are tested in animals whose immune responses are normal. In early development, animal studies assessing functional endpoints for immunotoxicity are generally not conducted at the same time as those using histopathological examination. Also there is no clear consensus on the level of immunological functional effects that can be considered adverse. This gap in our understanding between the type and grade of morphological changes and possible associated functional changes impacts our ability to determine adversity.

The purpose of this talk is to look at a range of changes seen in examining the immune system in a toxicological study and the decisions that have to be made when faced with making a call on adversity.

*Speaker Abstracts***S21: Adverse effects on the immune-system and beyond. Examples of immune effects in experimental animals and their relevance to humans.****Ruehl-Fehlert Christine***Bayer Pharma AG, Pathology & Clinical Pathology, Wuppertal, Germany*

In validation experiments with the immunomodulating drugs cyclosporine A and azathioprine, a high concordance between animal and human data has been shown previously (Kemmerling et al. 2015). In a subsequent validation study, increased sensitivity of immunohistochemical methods visualized histopathological findings at a lower dose of cyclosporine A than in previous studies. This raises the question how to define thresholds of adversity for immune effects. With azathioprine considerable differences could be found between subacute rat studies at similar dose levels. Bone marrow morphology and hematology were mostly affected in two studies but another study revealed predominantly thymus atrophy and only marginal indication of bone marrow changes. This could indicate, that immune findings can be more variable compared with those in other target systems.

In drugs causing immune-related unwanted side effects, often much less information is available than in drugs intended to modulate the immune system. Therefore, safety data from preclinical toxicity studies in animals derived from the Pharmapendium® database were searched for "blood and lymphatic system disorders". The most frequent findings in toxicological studies pertained to pathology and clinical pathology and included disorders of spleen, thymus, lymph nodes or bone marrow as well as hematological findings related to white blood cells. Regarding different experimental animal species, distinct differences in the proportion of findings could be found. With respect to therapeutic areas, immune related findings in animals were focused mostly on antineoplastic and immunomodulating drugs.

Regarding data of "blood and lymphatic system disorders" from clinical studies in humans derived from Pharmapendium®, prevailing findings were often related to granulocytes. When comparing preclinical and clinical studies, corresponding increases of immune findings could be observed for immunosuppression by immunomodulators and antineoplastic agents. In other therapeutic areas, the results were more difficult to interpret.

With respect to the assessment of adversity in animal studies, an understanding of the pharmacological target is instrumental. Considering the human situation, it would be desirable to further develop strategies for the prediction of idiosyncratic immune events as these are yet no relevant issue in routine toxicological studies.

References:

Kemmerling J. et al. (2015) Eur J Pharmacol 759, 326-342.

*Speaker Abstracts***S22: Pharmacological and adverse effects of immune modulators on the lympho-hematopoietic system. Example from rodents and non-rodents**

Junker Ursula, Heining Peter, Zamurovic-Ribrioux Natasa and Elhajouji Azeddine
Novartis Institutes for BioMedical Research– Preclinical Safety, Novartis Pharma AG, 4057 Basel, Switzerland



Due to the intended pharmacological action, compounds with immuno-modulating properties do have effects on the lympho-hematopoietic system. It is sometimes challenging to distinguish pharmacological from adverse effects. Moreover, also pharmacological effects can be adverse, if they become too extensive, especially in the context of toxicity studies where high doses are used. A few examples of effects of specific immune-modulators in rats, mice, dogs and minipigs are presented and discussed below.

Fingolimod is a sphingosine-1-phosphate (S1P) receptor modulator. S1P receptors are involved in the regulation of fundamental processes, including cell proliferation, angiogenesis, migration, cytoskeleton organization, endothelial cell chemotaxis, immune cell trafficking and mitogenesis. Fingolimod acts as a functional agonist of S1P receptors on lymphocytes. It blocks the capacity of lymphocytes to egress from lymph nodes, causing re-distribution rather than depletion of lymphocytes. Histological alterations in lymph nodes and thymus of rats treated with fingolimod are presented.

Everolimus is an mTor (mechanistic target of rapamycin) inhibitor. mTor is a serine/threonine protein kinase that regulates cell growth, proliferation, motility and survival, protein synthesis, autophagy and transcription. Everolimus inhibits T lymphocyte activation and proliferation that occurs in response to antigenic and cytokine (interleukin [IL]-2, IL-4, IL-7, and IL-15) stimulation (inhibition of the progression from the G1 to the S phase of the cell cycle). It inhibits intracellular proliferative signaling in activated T lymphocytes at FK binding protein 12 and the complex then binds to and inhibits the kinase mTOR. Besides other species (rodents and non-rodents), everolimus was also tested in minipigs and histological alterations in thymus, spleen, lymph nodes and intestinal tract are presented.

The paracaspase MALT1 (Mucosa-associated lymphoid tissue lymphoma translocation protein 1) plays an important role in immune receptor driven signaling pathways leading to NF- κ B activation. MALT1 promotes signaling by acting as a scaffold, recruiting downstream signaling proteins, as well as by proteolytic cleavage of multiple substrates. However, the relative contributions of these two different activities to T and B cell function are not well understood. To investigate how MALT1 proteolytic activity contributes to overall immune cell regulation MALT1 protease-deficient mice (Malt1^{PD}/PD) were generated. They developed inflammatory changes in multiple organs characterized by Th1 and Th2/o responses and enhanced IgG1 and IgE levels (Bornancin et al., 2015). Histological alterations in lymph nodes, stomach, salivary glands and peripheral nerves are presented.

SYK (spleen tyrosine kinase) is a receptor-proximal tyrosine kinase which plays an important role in adaptive immune receptor signaling, but also mediates other, diverse biological functions, including cellular adhesion, innate immune recognition, osteoclast maturation, platelet activation and vascular development. Several platelet functions are dependent on SYK and in SYK-deficient fetuses, blood-fil-

Speaker Abstracts

led structures are described that were identified to be blood filled lymphatic vessels (Mocsai et al., 2010). It can therefore be expected that SYK also participates in in vivo functions of platelets during hemostasis. Rats and dogs were treated with a SYK-inhibitor and histological alterations in lymph nodes are presented.

References:

Bornancin R, Renner F, Touil R et al., 2015. Deficiency of MALT1 paracaspase activity results in unbalanced regulatory and effector T and B cell responses leading to multiorgan inflammation. *J Immunol* 15;194(8):3723-34. doi: 10.4049/jimmunol.1402254. Epub 2015 Mar 11

Mocsai A, Ruland J, Tybulewicz VLC, 2010. The SYK tyrosine kinase: a crucial player in diverse biological functions. *Nature Reviews Immunology* 10: 387-402



*Speaker Abstracts***S23: Pattern recognition in complex systems to address adversity of effects on lymphoid organs and tissues****Kuper C. Frieke¹, Jack Vogels¹, Christine Ruehl-Fehlert² and Jessica Kemmerling²**¹TNO, Zeist, the Netherlands, ²Bayer Pharma AG, Wuppertal, Germany

The immune system is controlled by the endocrine and nervous systems, and influenced by host factors like age and (epi)genetics, and by external factors like exposure to pharmaceuticals. The immune system is highly dynamic and resilient and may also have a certain redundancy in order to function adequately. This complexity can make it difficult to evaluate induced changes in lymphoid organs. Data in animal safety studies are evaluated generally per parameter. Meta-analysis methods visualize patterns of responses, which can help to establish whether or not induced changes in lymphoid organs are adverse.

Aim

Information on the response per animal in addition to per parameter to improve the evaluation with respect to adversity of treatment-related findings and the translation of the results to man.

Methods

The results from immune-toxicity studies in rats with four different immunomodulator compounds were subjected to multivariate analysis, i.e. principal component analysis (PCA) and principal component discriminant analysis (PC-DA). The selected compounds were two pharmaceutical drugs: azathioprine (AZA) and cyclosporine A (CSA) and two environmental pollutants hexachlorobenzene (HCB) and benzo(a)pyrene (BaP).

Results / Conclusions

The PCA plots gave insight into the correlation between immune parameters. It also showed the main sources of variation in immune parameters. In the studies which included both sexes, it illustrated that the key pathology for males and females differed, but it did not reveal sex-related differences in sensitivity. Several treated animals were identified outside the 95% confidence limit indicating high-responders. Based on human data and/or mode of action the highest variation in response was expected in the AZA groups, but outstanding responders were also observed with CSA and HCB. This can be due to differences between rat and man. It may also be a reason to reconsider the expectation and re-examine the data, as multivariate analyses are tools to point to unexpected or overlooked results and correlations.

The correlation between parameters and the identification of outstandingly-responding animals can help to establish the adversity of treatment-related changes in lymphoid organs. The results of two voting's will be used to explore to what extent the meta-analysis methods are helpful.

References:

Kemmerling J. et al. (2015) Eur J Pharmacol 759, 326-342

Kuper CF et al. (2015). Eur J Pharmacol 759, 343-355

*Speaker Abstracts***S24: Interactive slide session: adversity of some induced immunostimulatory histopathology findings****de Jonghe Sandra¹ and Kuper C. Frieke²***¹Janssen Research & Development, Beerse, Belgium; ²TNO, Zeist, the Netherlands***Histopathology related to immune stimulation**

Slides will be presented of histopathology findings in a 2-week rat study with an immunomodulatory compound to compare the original judgement with the judgment of the audience on adversity. The observed findings were attributed to exaggerated pharmacology. The distribution, severity, and the type of findings were taken into account in the original judgement to decide on adversity. The compound induced changes in several haematology parameters and cytokines, but no optimal biomarker could be identified to follow up (non)adversity in vivo.



*Speaker Abstracts***S25: Immunotoxicity in Drug Development:
Mechanisms and Safety Assessment****Guionaud Silvia***MedImmune, Cambridge, UK*

Immunotoxicity due to potential new drugs has been a known phenomenon since the development of immunosuppressors like corticosteroids and cyclophosphamide. In addition, in recent years immunostimulatory antibodies for the treatment of cancer, and immunosuppressive antibodies for the treatment of autoimmune diseases, have increasingly entered development. Infusion reactions, cytokine storms, immunosuppression and autoimmunity are among the concerns when these drugs are administered. In addition to expected pharmacologic effects, unexpected effects on the immune system and secondary immunologic phenomena due to the formation of anti- drug antibodies can also be observed. The choice of relevant test systems and study designs, histopathology and clinical pathology findings, and suitable investigative endpoints will be discussed.



*Speaker Abstracts***S26: A novel, blocking anti-CD40 monoclonal antibody prolongs non-human primate renal allograft survival in the absence of B-cell depletion or thromboembolic events**

Wieczorek Grazyna¹, Cordoba Francisco¹, Audet Maxime², Schneider Martin A.¹, Espie Pascal³, Roth Lukas¹, Heusser Christoph¹, Bruns Christian¹, Patel Dhavalkumar¹, and Rush James S.¹

¹Novartis Institutes for Biomedical Research, Department of Autoimmunity, Transplantation and Inflammation, Basel, Switzerland; ²Hôpital de Hautepierre, Strasbourg, France; ³Novartis Institutes for Biomedical Research, DMPK, Basel, Switzerland

**Background**

CD40-CD154 pathway blockade significantly prolongs renal allograft survival in non-human primates (NHPs). However, antibodies targeting CD154 were associated with an increased incidence of thromboembolic complications precluding clinical development. Current antibodies targeting CD40 effectively prolong renal allograft survival in NHPs.

Aim

To address the question of the relative contribution of B-cell depletion to the efficacy of anti-CD40 blockade, we developed a novel, human Fc-silent anti-CD40 monoclonal antibody (CFZ533) that was incapable of antibody-dependent cellular cytotoxicity or complement-dependent cytotoxicity and tested it alongside an Fc-competent, B-cell depleting version of the same antibody in MHC-mismatched cynomolgus monkey renal allograft transplantation.

Results

Allograft survival was prolonged in animals treated with the Fc-competent anti-CD40 antibody (52, 22, 24 days) in comparison to untreated monkeys (survival ~ 7 days; n = 9). Well-functioning allografts survived up to 100 days in CFZ533-treated animals (100, 100, 100, 98, 78 days) at which point the experiment was terminated and graft morphology examined by histology. In contrast to good graft morphology in the CFZ533-dosed group, acute cellular rejection was observed in animals treated with Fc-competent anti-CD40. While both antibodies completely disrupted splenic germinal centers in transplanted animals (indicating a full tissue pharmacodynamic effect), peripheral blood B-cell depletion was only observed with the Fc-competent antibody. CFZ533 was well-tolerated and there was no evidence of thromboembolic events. Additionally, in most animals CFZ533 largely prevented a gene signature associated with acute rejection.

Conclusions

The data indicate that CD40 pathway blockade in the absence of B-cell depletion maintained very high allograft quality and function up to 100 days post-transplantation. Thus, use of the Fc-silent anti-CD40 antibody CFZ533 appears to be an attractive approach for preventing solid organ transplant rejection and treating autoimmune diseases involving T-cell-dependent humoral immune mechanisms.

Speaker Abstracts

References:

Cordoba F, Wieczorek G, Audet M, Roth L, Schneider MA, Kunkler A, Stuber N, Erard M, Ceci M, Baumgartner R, Apolloni R, Cattini A, Robert G, Ristig D, Munz J, Haerberli L, Grau R, Sickert D, Heusser C, Espie P, Bruns C, Patel D, Rush JS (2015). A novel, blocking, Fc-silent anti-CD40 monoclonal antibody prolongs nonhuman primate renal allograft survival in the absence of B cell depletion. *Am J Transplant.*; 15:2825-36.



*Speaker Abstracts***S27: Adversity Considerations in Clinical Pathology****Tomlinson Lindsay**

Pfizer Inc., USA



At the 4th ESTP International Expert Workshop (Palazzi et al 2016), adversity was defined in the following statement: In the context of a nonclinical toxicity study, an adverse effect is a test item-related change in the morphology, physiology, growth, development, reproduction, or lifespan of the animal model that likely results in an impairment of functional capacity to maintain homeostasis and/or an impairment of the capacity to respond to an additional challenge. With this definition in mind, an underlying premise to make adversity decisions for clinical pathology endpoints was discussed. The premise is that changes associated with adverse anatomic pathology or critical levels of clinical pathology endpoints associated with clinical adversity should be considered part of the constellation of adversity, but that clinical pathology findings should not be considered adverse in isolation. This interactive session will discuss considerations of adversity in cases where the test article produces off-target effects, pharmacologic effects with appreciation for the translation to people, and when critical values associated with specific clinical effects are observed. The following concepts will be covered: 1) If off-target effects are due to target selectivity differences not apparent in people (Tirmenstein et al 2013), adversity in nonclinical species may not be relevant in the clinic. 2) Pathogenesis is critical for determination of whether a clinical pathology finding is in the constellation of adverse findings or not. 3) When the desired pharmacology is potentially adverse to healthy volunteers, such as with glycemic control (Tirmenstein et al 2015), appropriate risk assessment (including the possible utility of animal models of disease) must be carefully considered. For some endpoints, critical values can be determined. These critical values are changes that are typically associated with a particular outcome such as thrombocytopenia and bleeding (Russell et al 2015). Even when a critical value is determined, the context of consistency and reproducibility of the effect must be assessed to fully understand adversity. The cases and discussion lead back to the proposed premise that clinical pathology endpoints, particularly individually, should not be considered adverse in isolation but in relation to the rest of the available nonclinical study data.

References:

Palazzi X, Burkhardt JE, Caplain H, Dellarco V, Fant P, Foster JR, Francke S, Germann P, Gröters S, Harada T, Harleman J, Inui K, Kaufmann W, Lenz B, Nagai H, Pohlmeier-Esch G, Schulte A, Skydsgaard M, Tomlinson L, Wood CE, and Yoshida M. (2016). Characterizing “Adversity” of Pathology Findings in Nonclinical Toxicity Studies: Results from the 4th ESTP International Expert Workshop. *Toxicol Pathol*; epub April 21, 2016.

Russell K. (2010). Platelet Kinetics and Laboratory Evaluation of Thrombocytopenia. In: Weiss DJ, Wardrop J, eds. *Schalm’s Veterinary Hematology*, 6th Ed., Ames: Wiley Blackwell; 576-585.

Tirmenstein M, Dorr TE, Janovitz EB, Hagan D, Abell LM, Onorato JM, Whaley JM, Graziano MJ, and Reilly TP. (2013). Nonclinical toxicology assessments support the chronic safety of dapagliflozin, a first-in-class sodium-glucose cotransporter 2 inhibitor. *Int J Toxicol*; 32 (5): 336-350, epub 4 October 2013.

Tirmenstein M, Horvath J, Graziano M, Mangipudy R, Dorr T, Colman K, Zinker B, Kirby M, Cheng PT, Patrone L, Kozlosky J, Reilly TP, Wang V, and Janovitz E. (2015). Utilization of the Zucker Diabetic Fatty (ZDF) Rat Model for Investigating Hypoglycemia-related Toxicities. *Toxicol Pathol*; 43(6): 825-837.

*Speaker Abstracts***S28: Are proinflammatory effects of antisense oligonucleotides in animals a clinical cause for concern?****Engelhardt Jeffery A.***Ionis Pharmaceuticals Inc., Carlsbad, CA 92010, USA*

Proinflammatory effects are a common “class-related” toxicity of antisense oligonucleotides (ASOs) where the toxicity is largely hybridization independent for the ASO in question. Several factors play into the magnitude to which proinflammatory effects are induced. Potency is dependent on sequence and length of the ASO, base modifications, and backbone chemistry (phosphorothioate [PS], 2'-MOE), particularly in rodents. Sequence specificity in rodents is related to activation of pathogen-associated molecular pattern (PAMP) receptors that leads to lymphohistiocytic cell infiltrates in a wide variety of tissues and increases in spleen weight accompanied by increases in inflammatory cytokines and chemokines, especially MCP-1. In nonhuman primates (NHP), ASO-mediated inflammation is generally dose related and due to activation of the alternative complement pathway via disruption of Factor H interaction with C3 convertase. This dysregulation of complement activation leads to failure to clear circulating immune complexes and often results in vascular injury and inflammation. While these particular alterations have not occurred in the clinical setting, proinflammatory effects are still noted as flu-like symptoms and injection site reactions with minor CRP elevations in patients in a dose and sequence-related manner. Even though the current understanding of mechanism indicates a limited clinical relevance of the effects in animals, diligent monitoring of safety across the platform provides additional comfort to the species specificity of the proinflammatory effects and relationship to dose.

References:

Burel SA, Han SR, Lee HS, Norris DA, Lee BS, Machemer T, Park SY, Zhou t, He G, Kim Y, MacLeod AR, Monia BP, Lio S, Kim TW, Henry SP. (2013). Preclinical evaluation of the toxicological effects of a novel constrained ethyl modified antisense compound targeting signal transducer and activator of transcription 3 in mice and cynomolgus monkeys. *Nucleic Acid Ther.* 23:213-227.

Burel SA, Machemer T, Ragone FL, Kato H, Cauntay P, Greenlee S, Salim A, Gaarde WA, Hung G, Peralta R, Freier SM, Henry SP. (2012). Unique MOE-DNA chimeric oligonucleotide induces an atypical MDA5 dependent induction of type I interferon response. *J Pharmacol Exp Ther.* 342:150-162.

Crooke ST, Baker BF, Kwoh J, Cheng W, Schulz D, Xia S, Salgado N, Bui HH, Hart CE, Burel S, Younis HS, Geary RS, Henry SP, Bhanot S. (2016). Integrated safety assessment of 2'-O-methoxyethyl chimeric antisense oligonucleotides in non-human primates and healthy human volunteers. *Mol Ther.* [Epub ahead of print]

Engelhardt JA, Fant P, Guionaud S, Henry SP, Leach MW, Loudon C, Scicchitano MS, Weaver JL, Zabka TS, Frazier KS. (2015). Scientific and Regulatory Policy Committee Points-to-consider Paper: Drug-induced vascular injury associated with nonsmall molecule therapeutics in preclinical development: Part 2. Antisense Oligonucleotides. *Toxicol Pathol.* 43:935-944.

Frazier KS. (2015). Antisense oligonucleotide therapeutics: The promise and the challenges from a toxicologic pathologist's perspective. *Toxicol Pathol.* 43:78-89.

Speaker Abstracts

Frazier KS, Engelhardt JA, Fant P, Guionaud S, Henry SP, Leach MW, Loudon C, Scicchitano MS, Weaver JL, Zabka TS. (2015). Scientific and Regulatory Policy Committee Points-to-consider Paper: Drug-induced vascular injury associated with non-small molecule therapeutics in preclinical development: Part I. Biotherapeutics. *Toxicol Pathol.* 43:915-934.

Henry SP, Seguin R, Cavagnaro J, Berman C, Tepper J, Kornbrust D. (2016). Considerations for the characterization and interpretation of results related to alternative complement activation in monkeys associated with oligonucleotide-based therapeutics. *Nucleic Acid Ther.* [Epub ahead of print]

Henry SP, Kim TW, Kramer-Stickland K, Zanardi TA, Fey RA, Levin AA. (2007). "Toxicologic properties of 2'-O-methoxyethyl chimeric antisense inhibitors in animals and man." In: *Antisense Drug Discovery: Principles, Strategies and Applications*. ST Crooke, ed. CRC Press. pp327-364.

Henry SP, Novotny W, Leeds J, Auletta C, Kornbrust DJ. (1997). Inhibition of coagulation by a phosphorothioate oligonucleotide. *Antisense Nucleic Acid Drug Dev.* 7:503-510.

Shen L, Engelhardt JA, Hung G, Yee J, Kikkawa R, Matson J, Tayefeh B, Macheimer T, Giclas PC, Henry SP. (2016). Effects of repeated complement activation associated with chronic treatment of cynomolgus monkeys with 2'-O-methoxyethyl modified antisense oligonucleotide. *Nucleic Acid Ther.* [Epub ahead of print]

Shen L, Frazer-Abel A, Reynolds PR, Giclas PC, Chappell A, Pangburn MK, Younis H, Henry SP. (2014). Mechanistic understanding for the greater sensitivity of monkeys to antisense oligonucleotide-mediated complement activation compared to humans. *J Pharmacol Exp Ther.* 351:709-717.

*Speaker Abstracts***S29: “Overcoming adversity” – steps to addressing potentially adverse histopathology findings in documents intended for regulatory submissions to FDA.*****Francke Sabine****US FDA CFSAN, College Park MD 20740, USA*

Identifying adversity, which could confound, delay or derail product development within a company, is only one of the many issues pathologists face; communicating adversity effectively to regulatory Agencies is another.

The objective of this presentation is to provide the audience with a list of points to consider intended to assist from a regulatory perspective with “overcoming adversity” once it has been identified in non-clinical studies. Carefully reporting diagnoses, clearly presenting respective data of adverse findings and logically providing substantiating arguments and their ramifications in documents intended for regulatory review, are key skills that minimize reviewer confusion and therefore regulatory delays after adversity has been identified in studies intended for regulatory submissions.

estp

European Congress of Toxicologic Pathology

*Speaker Abstracts***S30: Regulatory aspects of “adversity” in preclinical toxicity studies****Silva Lima Beatriz^{1,2}**¹ Universidade de Lisboa, Portugal ² NDA Advisory Board, UK

The European Regulatory guidances do not include a clear definition of adversity. A working definition has been proposed ESTP Working Group as follows: In the context of a nonclinical toxicity study, an adverse effect is a test item-related change in the morphology, physiology, growth, development, reproduction or life span of the animal model that likely results in an impairment of functional capacity to maintain homeostasis and/or an impairment of the capacity to respond to an additional challenge (Palazzi et al. 2016). The mechanisms behind adverse events may be related to the intended mode of action responsible by the therapeutic activity, which is more common with monoclonal antibodies, or they may be generated by additional mechanisms, triggered by the test compound or its metabolites. The mechanistic understanding of adversity is a fundamental component on determining its human relevance and, when possible, establishing management conditions.

Contrariwise to common chemicals, the regulatory decisions on medicinal products are mainly based on the judgment of the benefit/risk ratio associated to the product in the conditions of human use. Preclinical studies play a relevant role on i) the assessment of benefits, mostly related to the proof of concept, supportive of the understanding of the potential usefulness of the clinical candidate and of the justification for its experimental human administration in clinical trials and ii) predicting the potential human risks through the preclinical toxicity studies, also supporting the progress through clinical trials up to market.

Per definition, toxicity studies are expected to induce toxicity in the species chosen according to their human relevance, and doses may need adjustment when no toxicity has been observed at the maximum doses tested or below the maximum feasible dose (CPMP/SWP/1042/99 Rev 1 Corr*, 2010 and CPMP/ICH/286/95 ICH Topic M 3 (R2)). The absence of toxicity in a toxicity study reduces its predictive value and increases the level of uncertainty for the human translation, to establish the conditions of safe clinical use and limit doses. In this line, adverse effects/adversity identification in toxicity studies can be considered as preferable to complete absence of toxicity. Adversity forms the basis for the MTD, NOAEL (or even MABEL in case excessive pharmacology becomes the adverse effect) determination, as reference values for establishing the (initial) human dosing along clinical trials. Regulators are the gatekeepers expected to reassure society / patients on the safe conditions of medicines use. They are requested to analyse, interpret and evaluate the relevance of any findings in toxicity studies, with regard to the potential for and level of adversity, either for the species tested or as predictors of human adversity (EMA/CHMP/ICH/507008/2011). Irrespective of its predictive value for humans, adversity in the tested species will form the basis for the interpretation of the studies outcomes per se, eg justifying any organ dysfunctions up to mortality induced by the test compound. The subsequent human translation of the adversity observed in the species will depend on multiple integrated factors, including the mechanistic understanding for the adverse effects in the species and the potential for their occurrence in humans. For human relevant mechanisms, there is still a need for establishing the conditions for their occurrence or avoidability, eg dose dependency, duration of

Speaker Abstracts

administration, human health condition (eg pregnancy, liver or kidney or heart insufficiency, age, etc), the reversibility, etc.

While, for each type of adverse effect, the toxicologist and the pathologists may establish a judgment on its adversity and reach a conclusion in favor or against its classification as adverse/non-adverse, the regulatory decision will rather be based on the integrated evaluation of finding(s), the conditions of occurrence, and, most importantly, the human conditions justifying or not the medicine use, despite the identified risk, eg the severity of disease, existence of alternative therapies. As stated above, the benefit/risk decision will drive the weight put on an adverse event even if its severity is high. Several examples are available like anti HIV products, multiple anticancer products, etc. for which the benefit on eg increasing patient's survival and/or disease modification despite the high severity of the adverse effects generated in the preclinical studies justified its progress into the clinic. In addition to adversity identification and characterization, Regulatory decisions will include also determining the conditions (if any) for administration and treatment (eg per cycles for anticancer drugs) able to manage adversity when benefits are recognized that will justify and outweigh risks. The increasing, though still insufficient, pool of safety biomarkers (together with efficacy ones) are expected to contribute for a better management of adversity and will obviously impact on the regulatory decisions taken based on the adversity of drug-induced findings.

References:

Palazzi et al, 2016, Characterizing "Adversity" of Pathology Findings in Nonclinical Toxicity Studies: Palazzi et al, 2016, Characterizing "Adversity" of Pathology Findings in Nonclinical Toxicity Studies: Results from the 4th ESTP International Expert Workshop; Toxicologic Pathology Vol. 44(6): 810-824. DOI: 10.1177/0192623316642527.

CPMP/SWP/1042/99 Rev 1 Corr*, 2010; guideline on repeated dose toxicity:

http://www.ema.europa.eu/docs/en_GB/document_library/Scientific_guideline/2010/03/WC500079536.pdf

CPMP/ICH/286/95 ICH Topic M 3 (R2) Non-Clinical Safety Studies for the Conduct of Human Clinical Trials and Marketing Authorization for Pharmaceuticals.

EMA/CHMP/ICH/507008/2011; ICH guideline M3 (R2) - questions and answers; http://www.iss.it/binary/scf1/cont/ICH_M3_Q_A.pdf.

*Speaker Abstracts***S31: Review considerations for agrochemicals – moving forward in the evaluation and communication of adversity****Wood Charles**

EPA, USA



Histopathological findings in guideline toxicity studies are often used to derive health-based guidance values for agrochemicals. Currently there is a need for better consistency in the characterization of adversity decisions based on these findings.

This presentation will focus on interpretive and weight-of-evidence considerations in evaluating whether observed test article-related effects are adverse or not. Case examples from recent toxicological reviews of agrochemicals at the U.S. EPA will be presented, highlighting contextual issues, communication of adversity in pathology reports, and implications in risk assessment. Future directions related to integrating molecular and morphologic endpoints in adversity evaluations will also be discussed.



*Speaker Abstracts***S32: Industrial chemical-related thyroid tumors in rodents – do we need a review of the CLP-criteria?****Schulte Agnes***German Federal Institute for Risk Assessment, Berlin*

The Guidance on the Application of the CLP criteria* recommends that thyroid tumours in rodents mediated by UDP glucuronyltransferase (UGT) induction are not considered as relevant for humans. This is commonly agreed and applied by ECHA's Risk Assessment Committee when specific information in addition to standard carcinogenicity studies is available. Careful judgement is always needed to establish a rodent-specific mode of action for thyroid tumours.

Expert views published by EU Specialised Experts** and IARC*** in 1999 introduced a general concept on when rodent thyroid tumours should not be considered as relevant for humans. The available guidance documents are used for classification purposes or risk assessment on chemicals. In practice there is the particularity that their application may lead to different interpretations of the relevance to humans. While the use of the CLP Guidance would allow to disregard rodent thyroid tumours only if UGT induction has been proven as the mode of action, the EU Specialised Expert view applies criteria that in many cases will consider rodent thyroid tumours as not relevant.

Being in place since 1999, the existing guidance on the relevance of thyroid tumours to humans and the underlying species-specific mechanisms of thyroid tumour formation may need reconsideration. The validity of the approaches should be reviewed in order to verify that the knowledge gained during the last decades from new studies on thyroid-active substances is still in agreement with the previous recommendations.

Benefit will result if up-to-date criteria can be established and applied to interpretation of rodent thyroid tumours by regulators and industry conducting rodent carcinogenicity studies. The outcome may at best find acceptance as an internationally harmonised approach for several regulatory purposes. In practice, recent studies on the mechanisms of thyroid tumour formation in rodents and on epidemiology should be considered.

Thyroid tumours in rodents are of significance as effects on the thyroid including tumour formation may be considered as adverse and indicates an endocrine disruptive mode of action. Substances of concern can be identified as endocrine disruptive (ED) substance and may implicate further regulatory actions because of their ED character.

This talk will describe the issue from a regulatory perspective and does not intend to suggest readiness for a new framework of criteria. Rather, the author would like to recommend that an independent expert group may take the initiative.

Speaker Abstracts

References:

* Guidance to Regulation (EC) No 1272/2008 on classification, labelling and packaging (CLP) of substances and mixtures

**EU Commission Group of Specialised Experts in the fields of carcinogenicity, mutagenicity and reprotoxicity: Non genotoxic thyroid carcinogens in the rodent bioassay, ECBI/49/99 Add. 1 Rev. 2 excerpt of agenda point 3.1, 1999.

***IARC (1999) Scientific Publications No. 147 Species Differences in Thyroid, Kidney and Urinary Bladder Carcinogenesis.



Case Presentations

CPo1 Interactive Slide Session Pathology Cases

Franck Chanut,
Sanofi, Montpellier, France

CASE TITLE:	Adversity, Highest Non-Severely Toxic Dose (HNSTD) and Risk Assessment in the context of a cynomolgus monkey study for an anti-cancer drug. Comparison, overlaps and pitfalls.
ABSTRACT:	<p>We will present the results from one cynomolgus monkey study where target organs have been identified (only liver and bones will be presented).</p> <p>Adversity, severely toxic dose and risk assessment will be discussed in the context of this study and of the indication.</p> <p>We will conclude by comparing the data with the published literature to hypothesize a mechanism of action.</p>
Label on histoslides	N/A
ANIMAL(S):	
Species, breed	Cynomolgus monkeys
Sex	Males and Females
Age	Approximately 3 years old
Study type	14-day oral toxicity study
Treatment	Anti-FGFR ₄ small molecule
Clinical findings	/
Organ(s)	Liver and Bones
Gross finding(s)	None
Staining	N/A

Case Presentations

CONTRIBUTOR'S MORPHOLOGIC DIAGNOSIS:	What's your diagnosis?
CONTRIBUTOR'S DESCRIPTION AND COMMENTS:	
LITERATURE:	<p>Deng, C, Wynshaw-Boris A, Zhou F, Kuo, A, and Leder P (1996): Fibroblast growth factor receptor 3 is a negative regulator of bone growth. <i>Cell</i> 84, 911–21.</p> <p>Pai R, French D, Ma N, Hotzel K, Plise E, Salphati L, Setchell KDR, Ware J, Lauriault V, Schutt L, Hartley D, and Dambach D (2012): Antibody-mediated inhibition of fibroblast growth factor 19 results in increased bile acids synthesis and ileal malabsorption of bile acids in cynomolgus monkeys. <i>Tox Sci</i>; 126(2):446-56.</p> <p>Jacob AL, Smith C, Partanen J, Ornitz DM (2006): Fibroblast growth factor receptor 1 signaling in the osteo-chondrogenic cell lineage regulates sequential steps of osteoblast maturation. <i>Developmental Biology</i>; 296 315–328.</p> <p>Repena D and Ross P (2015): Targeting FGF19/FGFR4 pathway: A novel therapeutic strategy for hepatocellular carcinoma. <i>Diseases</i>; 3, 294-305.</p> <p>Yu C, Wang F, Kan M, Jin C, Jones RB, Weinstein M, Deng CX, and McKeehan WL (2000): Elevated cholesterol metabolism and bile acid synthesis in mice lacking membrane tyrosine kinase receptor FGFR4. <i>J Biol Chem</i>; 275(20):15482-89.</p>
ADDITIONAL COMMENTS:	<p>Toxic effects considered to be secondary to the direct inhibition of FGFR4 (i.e. liver and gallbladder) are considered to be relevant to humans, especially considering the protein homology with monkeys. Moreover, the clinical pathology changes observed seem to be translatable. In a clinical trial using a pan-FGFR inhibitor, dose limiting toxicity was hepatotoxicity with elevation of ALT/AST and the most common side effect was hyperphosphatemia (seen in 60% of patients) (Repena, 2015).</p> <p>Long bone changes are unlikely to be observed in human patient population (adults). The findings are occurring in a growing animal with active growth plate. Once closed, similar changes are not expected.</p>

Case Presentations

CPo2 Interactive Slide Session Pathology Cases

JoAnn C.L. Schuh,

JCL Schuh, PLLC (Consultancy), Bainbridge Island, USA

CASE TITLE:	Hard-Hearted Hounds
ABSTRACT:	This study was conducted to evaluate the long-term biocompatibility of a novel polymer injected into the left ventricular free wall of large mixed breed hounds (5 treated and 3 saline control male dogs per time point). Mortality of 1 control (during surgery; replaced) and 2 treated animals (within 20 days), was related to surgical complications. There were no bodyweight changes or changes in clinical pathology parameters or organ weights at interim histopathology on Days 90, 180 and 360 or at termination on Day 730 post-injection. Thoracic, pericardial and epicardial adhesions in controls and treated were attributed to surgical manipulations and injections. Due to limited histopathology information for spontaneous and background changes in mixed breed research hounds, sporadic changes may affect histopathology interpretation, determination of adversity and delay the risk assessment for medical devices.
Label on histoslides	Digital photomicrographs slides will be presented
ANIMAL(S):	
Species, breed	Canine (<i>Canis familiaris</i>), Mixed Breed Hound
Sex	Male
Age	9-32 mo
Study type	24-Month Toxicity, with interim evaluations
Treatment	Medical Device (Polymer), Intracardiac Injection
Clinical findings	Mortality of 1 control (during surgery; replaced) and 2 treated animals (within 20 days), was related to surgical complications. One control animal with premature ventricular contractions on ECG. Echocardiography identified thickening of the left ventricular free wall on Day 90 but not at subsequent time points.
Organ(s)	Heart
Gross finding(s)	Thoracic, pericardial and epicardial adhesions with restrictive pericarditis in mortality (attributed to the invasive surgical procedures)
Staining	H&E

Case Presentations

CONTRIBUTOR'S MORPHOLOGIC DIAGNOSIS:	What's your diagnosis?
CONTRIBUTOR'S DESCRIPTION AND COMMENTS:	
LITERATURE:	<p>Van Vleet J. 2001. Age-related non-neoplastic lesions of the heart. In: Mohr U et al., Pathobiology of the Aging Dog. ISU Press, Ames. pp. 101-117.</p> <p>Schwarz T, Sullivan M, Störk CK, Willis R, Harley R, Mellor DJ. 2002. Aortic and cardiac mineralization in the dog. Vet Radiol Ultrasound. 43:419-27.</p> <p>Douglass JP, Berry CR, Thrall DE, Malarkey DE, Spaulding KA. 2003. Radiographic features of aortic bulb/valve mineralization in 20 dogs. Vet Radiol Ultrasound. 44:20-7.</p> <p>Sandusky GE Jr, Kerr KM, Capen CC. 1979. Morphologic variations and aging in the atrioventricular conduction system of large breed dogs. Anat Rec. 193:883-902.</p>
ADDITIONAL COMMENTS:	

Case Presentations

CP03 Interactive Slide Session Pathology Cases

Heike Marxfeld,

BASF SE, Ludwigshafen, Germany

CASE TITLE:	Treatment-related vacuolation in Wistar rats in 90 day (gavage) studies with two chemicals – adverse or not?
ABSTRACT:	Treatment-related vacuolation was observed with two test items investigated in 90day (gavage) rat studies. The potential adversity of these findings will be discussed.
Label on histoslides	BASF 1
ANIMAL(S):	Wistar rats
Species, breed	CrI:WI(Han)
Sex	Male and female
Age	130 days
Study type	90d OECD 408
Treatment	2 chemicals
Clinical findings	None
Organ(s)	Test item 1: Brain, Eye, Lungs, Trachea Test item 2: Lung, liver
Gross finding(s)	Test item 1: none Test item 2: liver, enlarged, discoloration light brown
Staining	Test item 1: HE, Oil red O, PAS - alcian blue pH 2,5, EM Test item 2: HE, Oil red O, EM
CONTRIBUTOR'S MORPHOLOGIC DIAGNOSIS:	What's your diagnosis?
CONTRIBUTOR'S DESCRIPTION AND COMMENTS:	

Case Presentations

LITERATURE:	Ghadially, F N (1988) Ultrastructural Pathology of the cell matrix. 3rd ed. (Vol 1 and 2), Butterworths, London
ADDITIONAL COMMENTS:	



Case Presentations

CP04 Interactive Slide Session Pathology Cases

Lars Mecklenburg,

COVANCE Preclinical Services GmbH, Münster, Germany

CASE TITLE:	An example of nephrotoxicity in a Cynomolgus monkey treated with an Antibody-Drug Conjugate
ABSTRACT:	These slides are from a cynomolgus monkey that was intravenously treated with an Antibody-Drug-Conjugate. The antibody-component of this conjugate did not cross-react with the cynomolgus epitope. The warhead was not disclosed. The animal was treated twice with 21 days in between, and was euthanized after another 21 days.
Label on histoslides	CPSM1
ANIMAL(S):	n/a
Species, breed	Cynomolgus monkey, Mauritian origin
Sex	Female
Age	Approximately 3 years
Study type	Maximum feasible dose study
Treatment	Intravenous
Clinical findings	Mild increase in blood urea nitrogen [7.45 mmol/l versus 5.35 at predose] and creatinine [115.53 umol/l versus 88.17 at predose]
Organ(s)	Kidney
Gross finding(s)	Increased kidney weight
Staining	H&E, Immunohistochemistry for aquaporin-1, aquaporin-2, and calbindin
CONTRIBUTOR'S MORPHOLOGIC DIAGNOSIS:	What's your diagnosis?
CONTRIBUTOR'S DESCRIPTION AND COMMENTS:	

Case Presentations

LITERATURE:	<p>Bauchet AL, Masson R, Guffroy M, Slaoui M. Immunohistochemical Identification of Kidney Nephron Segments in the Dog, Rat, Mouse, and Cynomolgus Monkey. <i>Toxicol Pathol.</i> 2011; 39: 1115.</p> <p>Guha M, Heuer A, Price S, et al. Assessment of biomarkers of drug-induced kidney injury in cynomolgus monkeys treated with a triple reuptake inhibitor. <i>Toxicol Sciences.</i> 2011; 120 (2): 269-283.</p> <p>Hemmingsen C. Regulation of renal calbindin-D28K. <i>Pharmacol Toxicol.</i> 2000; 87 Suppl 3: 5-30.</p> <p>Knepper MA. The aquaporin family of molecular water channels. <i>Proc. Natl. Acad. Sci. U.S.A.</i> 1994; 91 (14): 6255–8.</p>
ADDITIONAL COMMENTS:	<p>It is hypothesized that the findings are caused by the warhead component of this compound. As a consequence of these findings, fluid and electrolyte balance are presumably impaired, and urine analysis (specifically measuring the specific gravity) as well as measurement of calbindin-28kd, clusterin, osteoactivin, or renal papillary antigen A-1 might be suitable biomarkers for early detection of nephrotoxicity.</p>



Poster Abstracts

Po1: A possible antitumoral effect of exercise-training on lesions induced by 1-Methyl-1- Nitrosourea in a rat model

Alvarado Antonieta^{1,2,3}, Faustino-Rocha Ana I.^{2,3,4}, Gil Da Costa Rui M.⁵, Lopes Carlos⁶, Ferreira Rita⁴, Oliveira Paula A.^{2,3} and Colaço Bruno²

¹ UCLA (Venezuela), ² UTAD, ³ CITAB-UTAD, ⁴ QOPNA, ⁵ LEPABE, ⁶ CI-IPOP: Department of Veterinary Sciences, School of Agrarian and Veterinary Sciences, University of Tras-os-Montes and Alto Douro, UTAD, Portugal

1-methyl-1-nitrosourea (MNU) is a nitrosocompound that acts as an alkylating agent and induces direct DNA damage. Depending on the rat strain, dose, route and age of administration, this compound has the ability to induce tumors in several organs. Thirty female Sprague-Dawley rats were divided into a sedentary and an exercise-trained group consisting of fifteen animals each one. All animals were administered a single intraperitoneal dose of MNU (50 mg/kg) at their 50th day of age. The animals from the exercise-trained group underwent 35 weeks of treadmill training by running at 20 m/min for 60 min/day for 5 days a week. Nine animals did not reach the planned study end and were excluded from the evaluation. The remaining 11 sedentary and 10 exercise-trained animals were humanely euthanized. All procedures followed the European (Directive 2010/63/EU) and National (Decree-Law 113/2013) legislation on the protection of animals used for scientific purposes and were approved by the Portuguese Ethics Committee (Approval no. 008961). At necropsy, the visible masses in the mammary region as well as the lung, liver, spleen and thymus were collected and evaluated histopathologically.

A total of 51 macroscopic mammary masses were identified: 28 in the sedentary and 23 in the exercise-trained group. At the histopathological evaluation (considering the predominant histological pattern in each mammary mass) was identified a total of 37 mammary lesions in the sedentary group and 32 in the exercise-trained one. Pre-neoplastic, benign, and malignant tumors were recorded according to the criteria described by Russo and Russo (2000), the malignant lesions (papillary carcinoma) being the most frequent ones. Even not being significant, the number of malignant lesions was lower in exercised group, when compared with the sedentary one. Moreover, two comedo invasive carcinomas were identified in the sedentary group, while the animals from exercised group did not develop any comedo carcinoma that was the most aggressive lesion identified in the present experiment. Macroscopic lesions like white stippling, white nodules and heterogeneous surface were observed in the lung, liver and kidneys from both experimental groups. At microscopic analysis, these lesions were classified as follows: two lung metastases of mammary adenocarcinoma in the sedentary group, two lung bronchioalveolar hyperplasias in each experimental group, four neoplasms in the kidneys from the sedentary group including nephroblastoma, parenchymal and mesenchymal malignant neoplasms, severe inflammatory changes like interstitial pneumonia and non-suppurative hepatitis in both experimental groups. Our study confirms the ability of MNU to act as a potent carcinogenic agent and to induce neoplastic changes in several organs in the rat. The results moreover suggest a potential

Poster Abstracts

beneficial role of exercise training on the induction of mammary tumors in the MNU-induced carcinogenesis model since they were less aggressive in their biological behavior.

Reference:

1. Russo J and Russo: Atlas and histologic classification of tumors of the rat mammary gland. J Mammary Gland Biol Neoplasia. 2000 Apr;5(2):187-200.



Poster Abstracts

Po2: Genetic Toxicity Battery of Perillaldehyde

Hayashi Shim-mo¹, Hobbs Cheryl^{1,2}, Beevers Carol³, Lloyd Mel³, Bowen Rachael³, Lillford Lucinda³, Taylor Sean⁴ and Maronpot Robert^{4,5}

¹ Japan Flavor & Fragrance Materials Association, Japan

² Integrated Laboratory Systems, Inc., Research Triangle Park, NC, USA

³ Covance Laboratories Ltd, Harrogate, UK

⁴ International Organization of the Flavor Industry, Washington, DC, USA

⁵ Maronpot Consulting LLC, Raleigh, NC, USA

Introduction: Perillaldehyde, a natural monocyclic terpenoid found most abundantly in the herb perilla, has a long history of use as a flavouring ingredient to add spiciness and citrus taste to foods. Perillaldehyde is designated by the Ministry of Health, Labour and Welfare in Japan as unlikely to harm human health, is affirmed as “generally recognized as safe” by the U.S. Flavor and Extract Manufacturers Association (FEMA), and was judged to be safe by the Food and Agriculture Organization of the United Nations/World Health Organization Joint Expert Committee on Food Additives (JECFA). In a program to confirm the safety of flavourings placed on the European Union list of flavourings, evaluation of the genotoxic potential of flavouring substances containing α,β -unsaturated aldehyde and ketone structures was requested. Perillaldehyde was selected as a representative of a subgroup of ten alicyclic aldehyde flavouring substances.

Methods: A genotoxicity battery consisting of a bacterial reverse mutation assay (Ames assay), an *in vitro* micronucleus assay in human lymphocytes, an *HPRT* assay in mouse lymphoma cells, and a micronucleus/comet assay in Wistar Han rats was conducted on perillaldehyde.

Results: Although previously reported *Salmonella typhimurium* strain TA98 assays were negative, perillaldehyde induced mutation in the absence of metabolic activation in TA98. The comet assay was negative for duodenum and weakly positive in liver, but only at a hepatotoxic dose of perillaldehyde as confirmed by histopathology. All other genotoxicity assays were negative.

Conclusion: These results reinforce the original conclusions of JECFA and the more recent reevaluation by the FEMA Expert Panel that perillaldehyde poses no safety concern for humans when used as a flavouring agent and consumed at estimated dietary exposures.

*Poster Abstracts***P03: Busulfan-induced non-proliferative lesions in a mouse time course study*****Cristofori Patrizia¹, Sanvito Francesca^{2,3} and Chanut Franck^{4,*}***¹ *GSK David Jack Centre for R&D, Park Road, Ware, Hertfordshire, SG12 0DP, UK*² *HSR-TIGET Ospedale San Raffaele, Via Olgettina 58/60, 20132, Milan, Italy*³ *Pathology Unit, San Raffaele Scientific Institute, Via Olgettina 58/60, 20132, Milan, Italy*^{*} *Now SANOFI, 371, avenue du Professeur Blayac, 34184, Montpellier, France*

Busulfan, an alkylating agent, has myeloablative properties and cytotoxic activity against non-dividing marrow cells. Its clinical use has been well established in the treatment of hematological malignancies (chronic myeloid leukaemia and other myeloproliferative syndromes). It is also commonly used (with or without cyclophosphamide) as a conditioning regimen for hematopoietic stem cell transplantation (HSCT) preclinically and clinically. Hemopoietic cell depletion is an expected change following administration of busulfan in mice. In addition, other changes might be observed such as lenticular degeneration and atrophy of reproductive organs. These lesions can interfere with the interpretation of preclinical toxicity and tumorigenicity studies performed to support the human clinical studies using allogeneic HSCT.

As such, it is important to understand the background incidence of busulfan-induced non-proliferative lesions.

We present preliminary results from a study where B6C3F1 mice were given 4 intraperitoneal injections of Busulfan (40 mg/kg, on days 0, 14, 28 and 42). Animals were sacrificed on days 126, 168, and 252. The histopathological lesions, their incidences and clinical pathology correlates are discussed on the poster.

All animal studies were ethically reviewed and carried out in accordance with Animals (Scientific Procedures) Act 1986 and the GSK Policy on the Care, Welfare and Treatment of Animals for Scientific Research.

*Poster Abstracts***Po4: A 26-week carcinogenicity study of FMS₃ in rasH2 transgenic mice****Wang Hemei, Yin Jiye, Qu Wensheng, Dong Yansheng and Wang Quanjun***Institute of Pharmacology and Toxicology, Academy of Military Medical Sciences,**100850, Beijing, China*

FMS₃ is a novel PPAR β/δ agonist developed for the treatment of some components of the metabolic syndrome such as diabetes, obesity and hyperlipidemia. To evaluate the carcinogenic potential of FMS₃, 10-week-old rasH2 mice of both sexes were dosed FMS₃ by oral gavage at 30, 60, 120 or 240 mg/kg/day for 26 weeks (n=50 per group). In addition, three groups of rasH2 mice of both sexes were used as the blank control (without any treatment, n=20), vehicle control (given same volume of 0.5% CMC-Na by gavage per day as the dosed groups for 26 weeks, n=50) or positive control (i.p. injection of urethane at a dose of 1000 mg/kg/d on day 1, 3 and 5, n=30). After 26 weeks of treatment, the survival rate was significantly lower in the positive control group compared to the blank control group (0% vs 89% in females and 0% vs 100% in males). No significant differences in the survival rate were found between the FMS₃ groups and the vehicle control group. Microscopic examination revealed that the most common tumors in the positive control group were bronchioalveolar adenoma/carcinoma of the lung (100% in both sexes) and hemangiosarcoma of the spleen (60% in females and 80% in males), both of which having significantly higher incidences in the positive control group compared to the blank control group (bronchioalveolar adenoma/carcinoma: 0% in both sexes; hemangiosarcoma of the spleen: 11.1% in females and 20% in males). Other incidental proliferative lesions in the positive control group included hemangioma of the lung, lymphoma and fibroma of the spleen, transitional cell carcinoma of the bladder, squamous cell carcinoma of the forestomach, hemangioma of the ovary, and adenocarcinoma of the thyroid. No differences were found between the positive control group and the blank control group with regard to the incidences of the above-mentioned tumors. The incidence of hepatic adenoma was increased in the male mice dosed 60, 120 and 240 mg/kg FMS₃ (44, 36 and 44%, respectively) compared to the vehicle control group (8%), while no hepatic adenoma was found in the female mice of the FMS₃ groups or vehicle control group. No other tumorigenic effects were found in the FMS₃ groups. In conclusion, our results in the positive control group and the blank control group were comparable to the data published in the literature. The results of this study suggest that the potential of FMS₃ to induce hepatic adenomas in male rasH2 transgenic mice is of concern.

*Poster Abstracts***P05: Histological and immunohistochemical characterization of Sunitinib efficacy on A498 human renal cell carcinoma xenografts in athymic nude CD-1 female mice**

*Defazio Rossella, Griffini Patrizia, Spagnolo Daniela, Criado Ana, Piccoli Laura and Gerrard Philip
Aptuit s.r.l., via Fleming, 4, 37135, Verona, Italy*

Sunitinib is a small molecule that has shown clinical efficacy in the treatment of advanced renal cell carcinoma (RCC), mainly inhibiting the tyrosine kinase activity of vascular endothelial growth factor receptors (VEGFR-1, VEGFR-2, and VEGFR-3)¹. The aim of this study was the histological and immunohistochemical characterization of Sunitinib effects on the tumor growth of A498 human RCC xenografts in athymic nude CD-1 mice after a 28-day treatment period (growth phase) and following a 1-week treatment-free period (regrowth phase). Sunitinib was subcutaneously administered once a day for 28 days by oral gavage at dose levels of 20, 40 and 80 mg/kg. Tumor xenografts were excised from the flank region, fixed in 10% neutral buffered formalin, and embedded in paraffin wax. Sections of approximately 4 µm thickness were prepared, stained with haematoxylin and eosin and evaluated microscopically for the following criteria: tumor size, mitotic index (MI), apoptotic index (AI), intratumoral necrosis and vascular mimicry (VM). To evaluate the extent of tumor angiogenesis, 4 µm-thick sections were immunostained with a primary rat monoclonal antibody directed against CD31. The endothelial area (EA) was measured using ImageJ analysis program in three 200x microscopic fields per section. At the end of 28-day treatment period, Sunitinib significantly reduced the tumor size and increased the extent of intratumoral necrosis in treated mice compared to concurrent controls. In treated mice, the tumor size was reduced with a dose-related trend up to 82% of control value. The extent of intratumoral necrosis was increased with a dose-related trend up to more than 80% of mass in treated mice as compared to the controls. VM-channels were more prominent in the central core of the mass compared to the periphery; the presence and extent of VM showed a time-related trend. A peripheral rim of surviving neoplastic cells was observed even in the most affected samples. After Sunitinib withdrawal, the tumor size in mice previously treated at 20 and 40 mg/kg/day was 15% and 6% respectively higher than the mice euthanized at term from the same dose groups. These changes were associated with an increase in the MI and with a decrease in the necrosis extent. Regrowth of tumor mass was observed only in one mouse previously treated at 80 mg/kg/day. At the end of 28-day treatment period, Sunitinib-treated mice showed a dose-related decrease in the EA up to 22.4 fold the control value. After Sunitinib withdrawal, the EA in mice previously treated at 20, 40 and 80 mg/kg/day was respectively 5.8, 4.1 and 8.6 fold higher than in mice euthanized at term from the same dose groups. The effects of Sunitinib on the EA were consistent with the described pharmacology: impaired angiogenesis and ingrowth of endothelial elements in treated A498 xenografts resulted in coagulative necrosis of the central, less perfused regions of the mass, that were more susceptible to ischemic injury; moreover, the regions of the tumors supplied by VM-channels were severely affected by treatment, confirming susceptibility of these complementary vascular structures to agents inhibiting VEGF pathway². A peripheral rim of surviving neoplastic cells was observed even in the most affected samples, allowing regrowth of the tumor mass and re-establishment of vascular network after treatment withdrawal.

Poster Abstracts

References:

1. Huang D, Ding Y, Li Y, Luo WM, Zhang ZF, Snider J, Vandenbeldt K, Qian CN, Teh BT. Sunitinib acts primarily on tumor endothelium rather than tumor cells to inhibit the growth of renal cell carcinoma. *Cancer Res*, 2010; 70(3):1053-62.
2. Chen YS and Chen ZP. Vasculogenic mimicry: a novel target for glioma therapy. *Chin J Cancer*, 2014; 33(2):74-9.



Poster Abstracts

Po6: Expression of molecules showing promoter region hypermethylation in the liver of rats treated with Thioacetamide for 28 days using a two-stage hepatocarcinogenesis model

Mizukami Sayaka^{1,2}, Yafune Atsunori^{1,2}, Watanabe Yousuke^{1,2}, Hasegawa-Baba Yasuko¹, Nakajima Kota^{1,2}, Yoshida Toshinori¹ and Shibutani Makoto¹

¹ Laboratory of Veterinary Pathology, Tokyo University of Agriculture and Technology, Japan

² Pathogenic Veterinary Science, United Graduate School of Veterinary Sciences, Gifu University, Japan

Introduction: Genomic methylation status can be inherited by daughter cells, and alteration of DNA methylation in the genome is found in almost all types of cancer, leading to changes in gene expression and acquisition of further growth advantages during cancer development. We hypothesized that hypermethylation-induced downregulation of genes during repeated carcinogen treatment may serve as early and irreversible marker for carcinogenic cellular responses. The aim of this study was to obtain hypermethylated genes after short-term hepatocarcinogen treatment and to establish molecular markers that direct hepatocytes toward carcinogenesis.

Materials and methods: CpG island methylation microarray analysis was performed on liver samples of rats treated for 28 days with the hepatocarcinogen thioacetamide (TAA) for 28 days. Genomic methylation profiles of TAA-treated rat livers were investigated by methylation-specific quantitative PCR and pyrosequencing, and transcript downregulation of hypermethylated genes by real-time RT-PCR. Protein expression and distribution of identified candidate genes was examined immunohistochemically in preneoplastic and neoplastic lesions in a classical two-stage hepatocarcinogenesis model applying hepatocarcinogens or promoters.

Results: Among 47 investigated genes, Hist1h2aa, encoding the histone H2A, Tmem70, encoding a mitochondrial membrane protein playing a role in biogenesis of ATP synthase, Ube2e2, encoding an E2 ubiquitin-conjugating enzyme and Slk, encoding a serine/threonine-protein kinase, were confirmed to be hypermethylated and downregulated at the transcript level by TAA treatment. Immunohistochemically, HIST1H2AA showed nuclear immunoreactivity and TMEM70, UBE2E2 and SLK showed cytoplasmic immunoreactivity in non-neoplastic hepatocytes of tumor promoted livers. Immunoreactivity of these molecules was decreased in preneoplastic hepatocyte foci positive for glutathione S-transferase placental form (GST-P), a preneoplastic liver cell marker, induced during tumor promotion. The incidence of TMEM70-/GST-P+ and UBE2E2-/GST-P+ foci was increased with tumor promotion by all hepatocarcinogens or promoters tested. Conversely, incidence of HIST1H2AA-/GST-P+ foci increased only by TAA promotion and incidence of SLK-/GST-P+ foci increased by tumor promotion only by TAA or piperonyl butoxide. Downregulation of TMEM70 and UBE2E2 was also achieved in GST-P+ tumors induced after long-term TAA treatment. The incidence of ATP synthase complex V beta subunit (ATPB)-/GST-P+ foci was increased with tumor promotion by all hepatocarcinogens and promoters examined. Moreover, glycolysis-related molecules, glucose transporter 1 (GLUT1) and glucose-6-phosphate dehydrogenase (G6PD), showed co-expression with GST-P and the incidences of GLUT1+/GST-P+ and G6PD+/GST-P+ foci were both increased by tumor promotion. On the other hand, the numbers of proliferating cell nuclear antigen (PCNA)+ cells and c-Myc+ cells in UBE2E2-/GST-P+ foci were increased compared to those in UBE2E2+/GST-P+ foci. In contrast, there was no change in p21Cip1 expression between UBE2E2-/GST-P+ foci and UBE2E2+/GST-P+ foci.

Poster Abstracts

Conclusion: These results suggest that TMEM70 and UBE2E2 may play a role as a tumor suppressor gene, showing epigenetic downregulation from an early stage onwards in hepatocarcinogenesis. TMEM70 may contribute to a metabolic shift from oxidative phosphorylation to glycolysis and UBE2E2 may contribute to cell proliferation through suppressing degradation of PCNA and c-Myc.



*Poster Abstracts***P07: *In vivo* reporter gene mutation and micronucleus assays in gpt delta mice treated with the flame retardant decabromodiphenyl ether**

Takasu Shinji¹, Ishii Yuji¹, Yokoo Yuh¹, Tsuchiya Takuya¹, Kijima Aki¹, Kodama Yukio², Ogawa Kumi-ko¹ and Umemura Takashi¹

¹ *Division of Pathology, National Institute of Health Sciences, Tokyo, Japan*

² *Division of Toxicology, National Institute of Health Sciences, Tokyo, Japan*

Polybrominated diphenyl ethers (PBDEs), a class of brominated flame retardants, have been widely used as additive flame retardants. There are growing concerns about environmental contamination and human exposure to PBDEs. Decabromodiphenyl ether (decaBDE), one of the PBDEs, is a hepatocarcinogen in rats and mice, although the incidence of hepatocellular tumors in dosed male mice was only marginally increased. Whereas one *in vitro* comet assay showed that decaBDE exerts a genotoxic effect, other *in vitro* studies such as Ames test, mouse lymphoma TK +/- assay, sister-chromatid exchanges or chromosomal aberrations test and the *in vivo* chromosomal aberration test on rat bone marrow samples were negative in previously performed experiments.

In the present study, we performed the micronucleus test on bone marrow samples and the reporter gene mutation assay on liver samples of gpt delta mice (mice transferred guanine phosphoribosyltransferase gene of *Escherichia coli* as a reporter gene), to clarify whether any decaBDE genotoxicity is induced *in vivo*. Six-week-old male B6C3F1 gpt delta mice were given decaBDE at concentrations of 0, 25000 or 50000 ppm in their diet for 28 days (n=5 each). Absolute and relative liver weights of mice treated with 25000 and 50000 ppm decaDBE were significantly increased compared with the control group animals. On microscopic examination, both groups treated with decaDBE had centrilobular hepatocyte hypertrophy in the liver. There were no intergroup differences in those changes. Negative results in the frequencies of the micronucleus test or the reporter gene mutation assay were shown between the groups. Thus, decaBDE did not exert genotoxicity at the carcinogenicity target site and did not show a positive result in the conventional *in vivo* genotoxicity test. Overall, our data indicate that non-genotoxic mechanisms are probably responsible for decaBDE-induced hepatocarcinogenesis. Further studies are necessary to clarify the non-genotoxic mechanisms underlying decaBDE-induced hepatocarcinogenesis, such as cell proliferation.

*Poster Abstracts***Po8: Comparison between developmental and post-pubertal stage exposure to N-methyl-N-nitrosourea on the effect of rat hippocampal neurogenesis**

Watanabe Yousuke^{1,2}, Nakajima Kota^{1,2}, Hasegawa-Baba Yasuko¹, Mizukami Sayaka^{1,2}, Akahori Yumi³, Imatanaka Nobuya³, Yoshida Toshinori¹ and Shibutani Makoto¹

¹ *Laboratory of Veterinary Pathology, Tokyo University of Agriculture and Technology, Japan*

² *Pathogenic Veterinary Science, United Graduate School of Veterinary Sciences, Gifu University, Japan*

³ *Chemicals Evaluation and Research Institute, Tokyo, Japan*

Introduction: N-Methyl-N-nitrosourea (MNU) is a DNA alkylating agent with genotoxic and therefore antiproliferative properties. A single bolus dose given to rodents during gestational day (GD) 13.0–15.5 causes lethal damage to proliferating cells, targeting neural stem/progenitor cells in the neuroepithelium of the dorsal telencephalon, and resulting in microcephaly. The present study examined the effect of developmental MNU exposure on adult hippocampal neurogenesis of rat offspring in accordance with the exposure scheme of OECD Test Guideline 426 adopted for developmental neurotoxicity. Because hippocampal neurogenesis continues throughout the life, we compared the effect of developmental exposure with that of postpubertal-stage MNU exposure on neurogenesis in a 28-day toxicity study using rats.

Materials and Methods: In the developmental exposure study, oral doses of MNU at 0, 3, 10 or 30 ppm in the drinking water were given to maternal SD rats from GD 6 to postnatal day (PND) 21. Neurogenesis-related parameters in the hippocampal dentate gyrus of male offspring were analyzed immunohistochemically and by real-time RT-PCR at the end of exposure on PND 21, as well as on PND 77 to examine reversibility. In the 28-day exposure study, 5-week-old male SD rats were treated with MNU at 0, 5 or 15 mg/kg by oral gavage for 28 days, and hippocampal neurogenesis-related parameters were examined similarly at the end of exposure.

Results: In the developmental exposure study, the number of GFAP+ subgranular zone (SGZ) cells decreased at 30 ppm compared to 0 ppm controls in offspring on PND 21. The number of SOX2+, TBR2+ or DCX+ SGZ/granular cell layer (GCL) cells, or TUNEL+ apoptotic SGZ cells or COX2+ GCL neurons in the hippocampal dentate gyrus increased at 30 ppm compared to 0 ppm in offspring on PND 21. Transcript levels of Grin2a decreased in the hippocampal dentate gyrus at 10 ppm on PND 21. On PND 77, the number of NeuN+ postmitotic SGZ/GCL neurons decreased at ≥ 10 ppm compared to 0 ppm. In the dentate hilus, the numbers of RELN+, PVALB+ or SST+ interneuron subpopulations did not change on both PND 21 and PND 77. In the 28-day exposure study, the number of GFAP+ or SOX2+ SGZ cells decreased at 15 mg/kg, and the numbers of TBR2+, DCX+ or NeuN+ SGZ/GCL cells, and ARC+ or COX2+ GCL neurons decreased at ≥ 5 mg/kg. The number of TUNEL+ apoptotic SGZ cells increased at 15 mg/kg. Transcript levels of Grin2a decreased in the hippocampal dentate gyrus at the 15 mg/kg dose level. In the dentate hilus, there were no changes in the numbers of RELN+, PVALB+ or SST+ interneuron subpopulations.

Discussion: The present study revealed that MNU targets type-1 stem cells by inducing SGZ cell apoptosis in both developmental and 28-day exposure studies. Considering the role of glutamatergic inputs on proliferation and differentiation in neurogenesis, type-1 stem cell reduction may be caused by

Poster Abstracts

downregulation of glutamatergic signals involving NR2A encoded by *grin2a*. Conversely, developmental exposure increased proliferating progenitor cells and postmitotic immature granule cells at the end of exposure, increasing neuronal plasticity. This probably reflected a compensatory response to stem cell reduction. In contrast, 28-day exposure decreased all SGZ/GCL cell populations, suppressing neuronal plasticity. The difference in impact on progenitor and postmitotic cell populations between developmental and 28-day MNU exposure might be caused by a difference in SGZ proliferation activity in these two study settings.



*Poster Abstracts***P09: Molecular mechanisms of cell proliferation contributing to the mutagenicity of estragole, a hepatocarcinogen***Ishii Yuji, Takasu Shinji, Kijima Aki, Ogawa Kumiko and Umemura Takashi**Division of Pathology, National Institute of Health Sciences, Tokyo, Japan*

Introduction: Estragole (ES), a hepatocarcinogen in rodents, induces ES-specific DNA adduct formation and gene mutations. Our recent study demonstrated that induction of cell proliferation is a prerequisite in the pathways leading from ES-specific DNA adducts to gene mutations. To understand the molecular mechanisms of ES-induced cell proliferation, we examined time-dependent changes of cell proliferation-related factors in the livers of gpt delta mice treated with ES.

Materials and Methods: Eleven-week-old female B6C3F1 gpt delta mice (5 mice/group) were given ES at a single dose of 100 or 300 mg/kg by gavage. The livers were collected at 1, 2, 3, 5, 7 and 14 days after the treatment. Histopathological examinations, immunohistochemical analyses for PCNA and cleaved caspase3, quantitative analysis of ES-specific DNA adducts by LC-MS/MS, gene expression analysis of cell cycle-related genes, and western blot analysis of cell cycle- and apoptosis-related proteins were performed in the livers of gpt delta mice given ES.

Results: In the high dose group, level of phosphorylated p53, p38 and JNK protein increased along with the maximum level of the ES-specific DNA adducts at day 1. Centrilobular hepatocyte apoptosis, cleaved caspase3-positive cells, increases of phosphorylated Akt, PP2A protein and Tnf gene expression were observed at day 2. Together with the hepatocyte mitosis, expression of cell cycle-related genes and PCNA-positive hepatocytes reached maximum levels at day 3. gpt mutant frequencies significantly increased at day 14. No necrotic changes were found through the experimental period. In the low dose group, there were no changes in all parameters examined in the present study except formation of ES-specific DNA adducts.

Discussion: Lack of both hepatocyte apoptosis and cell proliferation in the low dose group indicates that the two events play a key role in ES-induced mutagenicity. Phosphorylation of PP2A might contribute to signal transduction of cell proliferation.

Poster Abstracts

p10: Histological characteristics of spontaneous Glutathione S-Transferase placental form (GST-P) positive foci of hepatocellular alteration in male SD rats

Taniai-Riya Eriko¹, Kakimoto Kochi², Inagaki Koji², Yasui Yuzo¹, Kemmochi Yusuke¹, Anagawa-Nakamura Akiko¹, Toyoda Kaoru¹, Takahashi Akemi² and Shoda Toshiyuri²

¹ Toxicology Research Laboratories, Central Pharmaceutical Research Institute, Japan Tobacco Inc., Hadano, Kanakawa, Japan

² Biological/Pharmacological Research Laboratories, Central Pharmaceutical Research Institute, Japan Tobacco Inc., Hadano, Kanawaga, Japan

Introduction: Glutathione S-transferase placental form (GST-P) is known for its specific expression during rat chemical-induced hepatocarcinogenesis. Foci of cellular alteration (FCAs) which were positive for GST-P have been investigated in their role as useful preneoplastic marker. The chemical-induced GST-P positive FCAs are known to be mainly classified as either being of the eosinophilic or clear cell type. Recently, we found that some GST-P positive foci were not corresponding to any hepatocellular changes in regularly stained hematoxylin and eosin (H&E) serial sections of adult rats. We investigated the number and area of the spontaneous GST-P positive foci and those histological features using untreated male Sprague-Dawley (SD) rats of various ages.

Materials and Methods: The liver tissues were collected from male SD (CrI:CD) rats sacrificed at 4, 7, 12 and 26 months of age (n=10-20 per age), fixed in formalin and embedded in paraffin wax. The serial sections of the liver were stained with H&E and immunostained for GST-P. The number and area of GST-P positive foci were measured by morphometric analysis using a Leica virtual slide system and inForm image analyzer. GST-P positive foci were examined histopathologically and compared with the H&E sections.

Results: The number and area of GST-P positive foci increased with age. At 4 months of age, there were no GST-P positive foci with the exception of one single GST-P positive focus observed as eosinophilic FCA in one animal. At 7 months of age, GST-P positive foci were partially composed of eosinophilic hepatocytes. At 12 and 26 months of age, GST-P positive foci observed as partial eosinophilic hepatocytes were the highest in incidence (56% and 50% at 12 and 26 months of age, respectively), GST-P positive foci observed as eosinophilic FCAs were the next highest (29% and 30% at 12 and 26 months of age, respectively), GST-P positive foci not corresponding to any hepatic changes were the third in frequency (15% and 16% at 12 and 26 months of age, respectively), and GST-P positive foci observed as basophilic FCA or partially basophilic hepatocytes were the lowest in incidence (0% and 4% at 12 and 26 months of age, respectively). On the other hand, eosinophilic or basophilic FCAs negative for GST-P were observed from 12 months of age and the total number of GST-P negative FCAs was less than that of the GST-P positive FCAs per month. There were no clear cell FCAs in this study.

Discussion: We demonstrated that the number and area of the spontaneous GST-P positive foci increased with age in male SD rats. GST-P positive foci included not only eosinophilic FCAs but also partially eosinophilic hepatocytes at 12 and 26 months of age. At 7 months of age, all the GST-P positive foci were composed of eosinophilic hepatocytes but were not included as FCAs. Considering the number of GST-P positive hepatic changes and FCAs increasing with age, these findings indicate that morphological changes in the spontaneous FCAs occur following GST-P expression.

*Poster Abstracts***P11: Immunohistological investigation of genotoxicity, cell proliferation and apoptosis induced by inhalation of nanoscaled cerium oxide or barium sulfate**

*Schaudien Dirk, Schwotzer Daniela, Ernst Heinrich, Rittinghausen Susanne and Creutzenberg Otto
Fraunhofer Institute for Toxicology and Experimental Medicine ITEM, Hannover, Germany*

Introduction: Nanomaterials are gaining more importance in science and medicine, and are already widely used in various applications. Due to their diverse use, potential toxicological effects should be characterized. The two particles used in this study are expected to cover a wider range of different biokinetic behaviors and toxicological responses with barium sulfate being more rapidly cleared and less toxic.

Methods: A 90-day nose-only inhalation study in Wistar rats was conducted using 3.0 mg/m³ cerium oxide (NM-212) or 50.0 mg/m³ barium sulfate (NM-220). Clean air served as negative control. Five animals per group intended for immunohistology were sacrificed following one, 28, and 90 days of inhalation as well as after 28 and 90 days of recovery. The lungs were processed immunohistologically using antibodies to detect genotoxicity (8-OH-dG and γ H2AX), cell proliferation (Ki67), and apoptosis (cleaved caspase 3).

Results: The number of 8-OH-dG-positive cells per total number of cells counted was significantly increased in the lung parenchyma starting on day 90 of exposure and remained elevated until the end of the recovery period in the cerium oxide exposure group. Similarly, the number of γ H2AX-positive cells was significantly increased after 90 days of inhalation as well as after 28 and 90 days of recovery. In contrast, barium sulfate exposed animals did not show increased numbers of 8-OH-dG-positive or γ H2AX-positive cells at any time point.

Cell proliferation was additionally investigated by measuring Ki67-positive cells in the terminal bronchi and surrounding lung parenchyma. There was an increase in Ki67-positive cells after cerium oxide inhalation starting after 28 days of inhalation, which remained elevated during the whole recovery period in both lung compartments. Interestingly, inhalation of barium sulfate caused also increased numbers of Ki67-positive cells in the lung parenchyma after 28 and 90 days of inhalation. Furthermore, Ki67-positive cells were increased in the terminal bronchi following inhalation of barium sulfate after 90 days as well as after 90 days of inhalation followed by 28 days of recovery. In contrast, no increased numbers of cleaved caspase 3-positive cells were detected in any of the groups examined.

Discussion: Treatment with both particles resulted in increased cell proliferation in the lung. However, only inhalation of cerium oxide caused genotoxicity as detected by immunohistological markers such as 8-OH-dG- and γ H2AX. This seemed to reflect a higher toxicologic potency of cerium oxide compared to barium sulfate.

*Poster Abstracts***P12: Immunohistochemical characterization of immune system tumors in rasH2 mice*****Rittinghausen Susanne, Tillmann Thomas, Halter Roman and Schaudien Dirk****Fraunhofer Institute for Toxicology and Experimental Medicine ITEM, Hannover, Germany*

Malignant lymphomas are common tumors of the immune system in most strains of mice. Proliferative thymic lesions are frequently seen in addition. The differentiation of thymomas from malignant lymphomas and their subtyping has been a frequent subject of discussion in the past and was mainly performed using H&E slides. However, further characterization using immunohistochemistry is often helpful to subtype these lymphoproliferative lesions more reliably. In the risk assessment of pharmaceuticals and chemicals, 6-month studies using transgenic rasH2 mice are increasingly replacing carcinogenicity studies using conventional mice. In such studies, especially in treated (positive control) mice, tumors of the immune system are frequently observed. To gain background data, a 6-month study with 60 tg/wt and 60 wt/wt CByB6F1-Tg(HRAS)²jc male and female mice was conducted. 30 tg/wt and 30 wt/wt mice were treated initially with one intraperitoneal injection of N-nitroso-N-methylurea (positive control) at the dose of 75 mg/kg. At necropsy, all tissues were fixed in neutral buffered formalin for 24 hours and then transferred to 70% ethanol. Trimming and embedding in paraffin were performed within the following 3 days. In all animals, a full organ spectrum was histopathologically evaluated. For all mice with proliferative lesions of the immune system, the spleen, thymus, and additional tumor masses present were immunohistochemically investigated with markers for lymphocytes (anti-CD3, PAX5, CD45R, CD4, CD8), histiocytes (anti-F4/80), and keratinocytes (anti-pancytokeratin). Most tumors showed CD3-positivity. The detailed classification of the immune system proliferative lesions in RasH2 mice is presented on the poster.

*Poster Abstracts***P13: The use of in vivo and ex vivo compact magnetic resonance imaging (MRI) for the assessment of tumorigenicity following intrathecal transplantation of human embryonic stem cells (hESC) in NOD-SCID mice**

Schiffenbauer Yael¹, Amouyal Netanel², Ezov Nati², Steiner Michal², Izrael Michal⁴, Lavon Neta⁴, Hasson Arik⁴, Revel Michel⁴ and Nyska Abraham³

¹ Aspect Imaging, Shoham, Israel

² Envigo CRS, Ness Ziona, Israel

³ Consultant in Toxicologic Pathology, Timrat and Tel Aviv University, Israel

⁴ Kadimastem, Ness Ziona, Israel

Introduction: MRI of biological samples allows the thorough examination of the entire specimen using multiple digital slices, leaving the specimen intact for subsequent investigations, like histopathology. We tested MRI in a mouse model of teratoma induction, following a single intrathecal transplantation of hESC. This route was selected since it represents the intended clinical route of proprietary cells. The experiment was aimed to validate an appropriate positive control, assessing the feasibility of Compact MRI to detect teratoma induction.

Materials and Methods: Male 8 weeks old were used, 2 animals injected with the vehicle control and 3 injected with hESC. The cells or controls were injected within the inter-vertebral (L5 to L6) groove. Clinical evaluation was done daily. In-Vivo MRI was done at 2 occasions (days 25 & 48). The animals were sacrificed on day 55, and after formalin fixation, Ex-Vivo MRI was accomplished.

Results: Clinically, paresis developed in mice injected with the hESC. In-Vivo and Ex-vivo MRI located abnormal areas in the spinal column and brain.

Conclusion: The MRI was successful in localizing the induced teratoma, and the correlation to histopathology was done. The MRI technique is able to cover the whole mouse and, being non-invasive, can be used for time course observations of the carcinogenic changes.

Reference:

1. Tempel Bami C, Schiffenbauer Y, Nyska A, Abramovitch R, Ezov N, Spector I, Maronpot RR (2015) Practical Applications of in vivo and ex vivo MRI in toxicologic pathology using a novel high-performance compact MRI system. *Toxicologic Pathology* 43(5):633-50.

*Poster Abstracts***P14: Investigating small molecule liver toxicity by Matrix-Assisted Laser Desorption/Ionization-Image Mass Spectrometry (MALDI-IMS)**

Maganti Rajanikanth¹, Hronowski Xiaoping², Kamel Amin³, Stone Ivan¹, Tien Eric¹, Juhasz Peter², Guckian Kevin², Fikes Jim¹ and Polack Evelyne¹

¹ Preclinical Safety, ² Chemical & Molecular Therapeutics, ³ Drug Metabolism & Pharmacokinetics, Drug Discovery, Biogen, Inc. Cambridge, MA, USA

Investigation of drug-induced toxic liabilities observed in preclinical safety studies can be an important step in the go/no-go decision in drug development. Drug biodistribution in preclinical studies is routinely evaluated by using whole body autoradiography or positron emission tomography. However, these methods require radiolabeling and do not provide information on the drug metabolites. Other methods like Liquid Chromatography Mass Spectrometry can identify compounds from tissue but require homogenization and, thereby, do not preserve tissue morphology. MALDI-IMS is an emerging label-free approach that enables multiplexed *in situ* detection of lipids, proteins and peptides as well as drugs and their metabolites by direct analysis of fresh frozen tissue sections. Liver toxicity as observed with many small molecule compounds is an apt indication to investigate drug localization using MALDI-IMS in the context of the hepatic histomorphological changes. The objective of the present study was to evaluate the application of MALDI-IMS as a 'proof-of-principle' in preclinical safety to investigate the potential co-localization of the hepatic vacuolar change and the administered small molecule parent compound, and/or any major metabolite(s). Representative compound-treated and control frozen liver sections from a 14-day rat toxicity study were analyzed using a Bruker 7T Fourier Transform Ion Cyclotron Resonance (FTICR) MALDI-IMS instrument that allows to define molecular identity with high mass accuracy and -spatial resolution. MALDI-IMS revealed compound distribution that correlated with morphologic pattern of hepatic vacuolar change. Identity of the compound in treated-liver sections was confirmed by comparing the spectral profile of the purified compound spiked as gradient dilutions on control liver sections. The relative concentration of the compound was estimated across the various dose groups and samples with different vacuolation severity scores. Furthermore, spatial distribution pattern and mass spectra of lipid species in compound-treated liver samples were compared to control. MALDI-IMS generated images were co-registered and compared with routine hematoxylin-eosin histology and histochemical stain for lipids. Findings demonstrate that MALDI-IMS is a promising complementary method to investigate drug distribution and provide *in situ* molecular information at the basis of preclinical toxicological pathology findings.

*Poster Abstracts***P15: Molecular target validation in human atherosclerosis based on mass spectrometry imaging and immunohistochemistry studies**

Hamm Gregory¹, Aldi Silvia², Masure Juliette¹, Holmstrøm Kim³, Arda Serife⁴, van Keulen Danielle^{5,7}, Bobeldijk-Pastorova Ivana⁵, Tempel Dennie⁷, Nielsen Boye S.³, Gudo Michael⁴, Lindeman Jan NH⁸, Hedin Ulf², van Gool Alain J.⁵, Hurt Camejo Eva⁶ and Stauber Jonathan¹

¹ *ImaBiotech, MS Imaging Dept., Loos, France*

² *Department of Molecular Medicine and Surgery, Karolinska Institutet, Stockholm, Sweden*

³ *Bioneer, Hørsholm, Denmark*

⁴ *Morphisto, Frankfurt am Main, Germany*

⁵ *TNO, Zeist, The Netherlands*

⁶ *AstraZeneca R&D, Mölndal, Sweden*

⁷ *Quoris, Rotterdam, The Netherlands*

⁸ *Leiden University Medical Center, Leiden, The Netherlands*

Mass spectrometry imaging is used in combination with other advanced imaging modalities to validate molecular target within atherosclerotic plaque. The elucidation of mechanisms underlying the formation of atherosclerotic plaque in the inner lining of the artery wall is the basis for identification of novel targets to treat cardiovascular disease. High quality validation of these candidate targets is imperative to drive later success in the drug development process. Within the CarTarDis consortium, multiple molecular imaging modalities have been used to improve the efficacy of the validation step. Mass Spectrometry Imaging was combined with immunohistochemistry to spatially correlate cell subtypes, enzymes expression and molecular biomarkers in human atherosclerotic plaque tissues. Thanks to the high spatial and spectral resolutions allowed by mass spectrometry imaging (MSI), we localized metabolites in specific regions which might provide new insights into atherosclerotic process. Human carotid plaques obtained from human Biobank of Karolinska Endarterectomies (BiKE, Karolinska Institutet, Stockholm, Sweden) were used as analytical material. Snap frozen plaque tissue was sectioned and thaw mounted on ITO/Superfrost glass slides to enable multimodal analysis. DHB and 9AA were respectively used as MALDI matrices for positive and negative detection modes. Two matrix application methods were used: the classical way with SunCollect sprayer device (SunChrom) and the sublimation process using an home-built apparatus. Mass spectrometric images were performed in positive or negative detection mode using a Solarix MALDI-FTICR 7.0T Mass Spectrometer (Bruker Daltonics) at high spatial resolution. Data were generated, analyzed and combined using Multimaging software (ImaBiotech, France). For immunohistochemistry, a probe-polymer system containing alkaline phosphatase was applied to the sections, with subsequent detection using Vulcan Fast Red. Our preliminary data showed that mechanisms related to lipid metabolism and inflammation are genetically and functionally linked to cardiovascular disease (CVD). PPAP2B (Phosphatidic Acid Phosphatase Type 2B) gene encodes for the lipid phosphate phosphohydrolases 3 (LPP3) that hydrolyze and inactivate lysophosphatidic acid (LPA) and sphingosine-1-phosphate (S1P). CECR1 (Cat Eye Syndrome Chromosome Region, Candidate 1) converts adenosine into inosine and regulates inflammation. As potential key nodes in these mechanisms, we decided to further investigate the metabolites associated with PPAP2B and CECR1 by multimodal molecular imaging. Our results showed that in atherosclerotic plaque LPA and S1P were detected as well as phosphatidic acid, diacylglycerol

Poster Abstracts

and lysophosphatidylcholine related ions. These results were then combined with PPAP2B immunostaining on adjacent tissue sections. A close co-localization of LPAs with this enzyme was observed in the fibrous cap of the human carotid plaque. Moreover, cholesterol was targeted as marker of necrotic core region of the plaque. A quantitative measurement of co-localization of molecular species pixel per pixel of molecular species on MS image was performed based on coefficient of determination. For CECR1 studies, adenosine, inosine and their phosphate forms were analyzed on consecutive sections of human carotid plaque and combined with macrophage proliferation in tissue. Interestingly, adenosine and inosine were co-localized in the same histological region of the plaque, suggesting that they may be used to measure CECR1 activity in-situ. Here we show a new application of mass spectrometry imaging in early phases of drug discovery process to provide reliable data on molecular target validation in human pathological tissue. This project is funded by the EU Seventh Framework Program (FP7/2007-2013) under grant agreement N°602936 (CarTarDis project).



*Poster Abstracts***P16: Optical imaging techniques to monitor stem cell distribution in preclinical applications**

Roh Hang-Sik, Seok Ji-Hyun, Yu Hye-Sun, Cho Saet-byul, Choi Hye-Kyung, Kim Ye-Seul, Yang Jun-Young, Cho Soo-Yeu and Jeong Ja-Young

Toxicological Research division, National Institute of Food and Drug Safety Evaluation, 187, Osongsaengmyeong 2-ro, Osong-eup, Heungdeok-gu, Cheongju-si, Chungcheongbuk-do 28159, Republic of Korea

Stem cell-based therapy has excellent potential for the treatment of a wide variety of diseases due to the intrinsic properties of stem cells, which include self-renewal capacity and pluripotency. Direct evaluation of stem cell therapy efficacy has emerged as an area of great research interest. There is an as yet unmet need for reliable methods that can monitor distribution of stem cells after administration to the body with high reproducibility of experimental results and limited use of experimental animals. Despite much effort, no suitable guidelines on the use of methods to monitor stem cell distribution in preclinical studies have thus far been published. The aim of this study was to provide a guideline on the evaluation of stem cell distribution through optical imaging techniques by comparing two methods: fluorescence and bioluminescence.

In the first method, stem cells (i.e. mesenchymal stem cells (MSCs) or embryonic stem cells (ESCs)) were labeled with two lipophilic near-infrared (NIR) fluorescent dyes, dioctadecyltetramethyl indotricarbocyanine iodide (DIR) and Vivo Track 680, and imaged by fluorescence. In the second method, stem cells (MSCs or ESCs) were transduced with a combined vector containing firefly luciferase and green fluorescent protein (Luc-GFP), and imaged by bioluminescence. ICC and MTS assays were conducted and showed that labeled and unlabeled cells had the same properties. After intravenous injection, NIR labeled cells were detected in the lung, liver and spleen. Conversely, Luc-GFP-transduced cells were found to disperse from the lung at an early stage following administration and distributed widely through the entire body within a one week period.

Our results showed that bioluminescence imaging was more sensitive than fluorescence imaging and provided preliminary guidelines on how to monitor stem cell distribution in the body in preclinical applications.

*Poster Abstracts***P17: Tissue Mass Spectrometry Imaging as a tool for drug candidate selection: tissue distribution and relationship to toxicity.**

Slaoui Mohamed¹, Legouffe Raphael², Bonnel David², Olivier Olivier¹, Valente Delphine¹, Ducelier Cécile¹, Krick Alain¹, Mauriac Christine¹, Stauber Jonathan² and Palazzi Xavier¹

¹ Sanofi R&D, Paris, France

² ImaBiotech, Lille, France

Continuous improvements of Tissue Mass Spectrometry Imaging (tMSI) in terms of sensitivity, mass and spatial resolution have progressed this imaging approach into a more robust and routine technique. This modality can now be applied to support drug development by providing a variety of biological investigations. These encompass tissue distribution of drug and metabolites as well as co-localization of drug and metabolites with specific histological findings in toxicity studies.

Most up-to-date tMSI techniques enable in situ drug/metabolites quantifications in tissues, bringing significant added value over classical direct quantification on tissue homogenates.

tMSI can nicely complement histopathology and other imaging modalities such as autoradiography and Positron Emission Tomography (PET).

This poster describes the results of a supportive tMSI study designed to address a safety issue of a diabetes candidate compound in the kidney of CrI:CD(SD) Sprague Dawley rats treated once daily for 2 weeks by oral route. In this study tMSI was performed on transversal sections of the left kidney while full metabolite profile was measured from micro-dissected homogenates of the cortex and the medulla from individual contralateral kidneys.

*Poster Abstracts***P18: Examples of Drug-Related Immune Effects in Preclinical Toxicological Studies and Clinical Studies Based on a Data Search in the Pharmapendium ® Database*****Ruehl-Fehlert Christine****Bayer Pharma AG, Pathology & Clinical Pathology, Wuppertal, Germany*

Systematic data on immune findings linking routine toxicological studies in animals with corresponding human data from clinical studies may improve the understanding of drug-related immune effects. The Pharmapendium ® database was searched for safety data on „blood and lymphatic system disorders“. Findings related to immune changes were further analyzed. Different scoring systems had to be applied for preclinical and clinical studies. The scoring was performed with reference to individual findings and frequency of their occurrence. In animal studies, in addition the observation in one or multiple species was considered.

Cyclosporine A is an example of an immunomodulating drug leading to intended immunosuppression in animals and humans related to the pharmacological target of calcineurin inhibition. As higher doses were applied in toxicological studies than in clinical investigations in humans, the findings were clearly more pronounced and multifaceted in animals.

Examples of other drugs showing immune effects in humans and animals are given. The cause of these changes is often not well understood and thus it is difficult to translate animal to human findings and vice versa.

In addition, in humans predictable dose-related side effects may be superimposed by unpredictable, idiosyncratic immune changes. A better understanding of immune changes in animal studies and their further characterization in preclinical mechanistic and immune functional studies is instrumental for human safety.

*Poster Abstracts***P19: Safety assessment of T cell bispecific antibodies targeting FOLR1 in cynomolgus monkeys**

Giusti Anna Maria¹, Hinton Heather¹, Bray-French Katharine¹, Lechmann Martin¹, Funk Jurgen¹, Ott Virginie¹, Jacobsen Bjoern¹, Richardson Marion¹, Husar Elisabeth¹, Wolz Erich¹, Bruenker Peter², Freimoser Grundschober Anne², Weinzierl Tina³, Sam Johannes³, Umaña Pablo³ and Klein Christian³
Roche Pharma Research and Early Development

¹ Pharmaceutical Sciences

² LMR

³ Oncology Discovery

Folate receptor (FOLR1) is a cell surface protein whose aberrant expression in malignant cells has resulted in its pursuit as a therapeutic target and marker for diagnosis of cancer.

A FOLR1-CD3 T cell bispecific antibody targeting FOLR1 was administered intravenously to cynomolgus monkeys as part of a pharmacokinetic study at doses of 0.3 µg/kg to 10 µg/kg. Treatment resulted in clinical respiratory distress and euthanasia 24h after dosing in two animals at 10 µg/kg. At necropsy mottled lung lobes, pale fluid accumulation in the trachea and reddened adrenal glands were noted. Histopathology identified multifocal polymorphonuclear infiltration in several organs and decreased cellularity of lymphoid tissues.

A variant of the FOLR1-CD3 T cell bispecific antibody with ~20x lower monovalent affinity for FOLR1 and a broader in vitro window between killing of tumor cell lines and normal cells, but retaining in vivo efficacy in xenograft models, was developed and administered to cynomolgus monkeys as part of a tolerability study.

Single intravenous administration at 10 or 30 µg/kg resulted in a decrease of lymphocytes and an increase in neutrophils counts noted 24-48 hours after treatment at all doses, but no pathological changes in the lung were observed. Fibrinogen and CRP were elevated at ≥ 10 µg/kg 48 hours after dosing, indicating an acute phase response. Notably, abnormal cloudy appearance of the eye was observed at 10 µg/kg. Microscopically, mononuclear cell infiltrate was noted in the iris and ciliary body, and exudate in the anterior and posterior chambers. In addition, mixed cell infiltrate was observed in the choroid plexus of the brain.

Evaluation of FOLR1 expression at the protein and mRNA level in cynomolgus monkey tissues confirmed expression in the choroid plexus of the brain, lung alveolar pneumocytes and ciliary body in the eye.

The changes observed in monkeys treated with two T cell bispecific antibodies targeting FolR1 suggest cell-mediated cytotoxic activity in organs/tissues where FOLR1 is expressed, resulting in local chemokine release and an acute inflammatory response. This interpretation is supported by the rapid decline of antibody concentrations in peripheral blood for the high affinity FOLR1-CD3 T cell bispecific antibody, suggesting Target Mediated Drug Distribution (TMDD), whereas lower TMDD was observed for the low affinity variant. It can be hypothesized that the different affinity of the two antibodies for FolR1 may have influenced the distribution of the microscopic changes.

*Poster Abstracts***P20: Trauma as a cause for hepatopathy in newborn Göttingen minipigs: a procedure-related finding complicating interpretation of toxicity studies**

Ramot Yuval¹, Weber Klaus², Moreno Lobato Beatriz³, Sánchez Margallo Francisco Miguel³, Guillén Caro José Francisco³, Dávila Gómez Luis³, Shabat Roni⁴ and Nyska Abraham⁵

¹ Hadassah – Hebrew University Medical Center, Jerusalem, Israel

² AnaPath GmbH, Oberbuchsitzen, Switzerland

³ Centro de Cirugía de Mínima Invasión (CCMI), Cáceres, Spain

⁴ Roni Shabat CCMI Israel Ltd, Nazareth, Israel

⁵ Sackler School of Medicine, Tel Aviv University and Timrat, Israel

Introduction: Routine maintenance procedures can lead to incidental pathological changes that may influence the interpretation of animal toxicity studies. We report observed trauma-induced hepatopathy in newborn Göttingen minipigs.

Experimental design: 64 neonatal minipigs were allocated to 13- and 26-week treatment arms. There was a 4-week recovery period for both arms. The animals were divided into two treatment groups and a vehicle group, which underwent similar dosing procedures as the test compound-treated groups. Dosing was three times daily by direct oral administration with a syringe.

Methods: Macroscopic and microscopic evaluation of the gastrointestinal system, including the liver, was performed.

Results: During the first weeks of administration, dosing of the animals was not voluntary and the caretakers had to pick up the animals on their arms. When the animals resisted, a second caretaker assisted by opening the animal's mouth and administering the syringe deep enough to ensure administration. The dosing time could take up to 2 hours during the first weeks. The animals went through daily training, and after approximately three weeks were voluntarily dosed without restraint. The livers from the 13-week arm revealed randomly distributed foci of degeneration/necrosis, and focal congestion and/or hemorrhage, mainly at a subcapsular location in several animals from all groups, including controls. In the 26-week sacrifice point, only one animal had multifocal, subcapsular fibrosis in the liver. A potential infectious cause was investigated and excluded.

Conclusion: Both acute and chronic lesions were observed, reflecting the different periods during which liver trauma occurred. Hepatopathy can be observed as an incidental finding following the manual firm handling of animals, especially newborn minipigs, which are highly susceptible to hepatic trauma.

Impact statement: If the manual handling of the animals may cause intra-abdominal trauma, the presence of foci of degeneration/necrosis, associated with hemorrhage, in the livers of newborn minipigs may be considered as a trauma-related consequence.

*Poster Abstracts***P21: The evaluation of intestinal toxicity caused by indomethacin in zebrafish (*Danio rerio*).****Ryu Bokyeong, Oh Han Seul, Kim Wook Jin, Kim C-Yoon, Jung Cho-Rok and Park Jae Hak***College of Veterinary Medicine, Seoul National University, Korea Research Institute of Bioscience & Biotechnology, Korea*

Introduction: Evaluation of intestinal toxicity is important because the gastrointestinal (GI) tract mucosa functions as the first barrier to xenobiotics taken orally. The rat is the standard animal model for testing intestinal toxicity, but can have certain limitations regarding affordability and ethical concerns. In addition, rat GI tract mucosa lacks cytochrome P450 3A expression found in humans. Caco-2 cells also lack expression of cytochrome P450 3A, and like all in vitro cultured cell lines, cannot model the complex tissue and organ level cellular interactions present in vivo. In this study, we investigated whether zebrafish can be used as a valid alternative model for intestinal toxicity testing. Zebrafish are relative easy to keep, compliant with 3R principles, have over 70% genetic homology with humans, and express a cytochrome P450 3A4 homologue (i.e. CYP450 3A65) in their GI tract mucosa.

Methods: Male zebrafish and male Sprague-Dawley rats were used in this study. The zebrafish were kept at a density of 1 fish per 200 mL tank water, which either contained indomethacin (LC₅₀*100.25n mg/DMSO 0.5 mL/L, n=0, -1) or vehicle (DMSO 0.5 mL/L). Rats were administered either a single oral dose of indomethacin (LD₅₀*100.25n mg/10% Tween 80 2 mL/kg body weight, n=0, -1) or vehicle (10% Tween 80 2 mL/kg body weight). Zebrafish were sacrificed after 6, 12 or 24 hrs of indomethacin exposure with MS-222 (Tricaine, 120 mg/L tank water) and rats at the same time points following treatment using CO₂ asphyxiation.

Real-time polymerase chain reaction (PCR) analysis was conducted on pooled RNA samples (n=5/group) isolated from either whole fish intestine or the distal third part of rat small intestine. Total RNA was isolated from tissues or cells using the GeneAll® Hybrid-R™ (Seoul, Korea) assay. One microgram of RNA was reverse transcribed using a BIONEER AccuPower® RT PreMix (Daejeon, Korea) to obtain cDNA according to the manufacturer's protocol. Briefly, a total reaction volume of 20 µL was incubated in a Bio-Rad T100™ Thermal Cycler as follows: 5 min at 70°C and placed on ice, 60 min at 42°C, 5 min at 94°C, and then stored at 4°C. Next, Real-time PCR was performed with a Bio-Rad Real-time PCR System CFX Connect™ using Enzynomics TOPreal™ qPCR 2x PreMIX (SYBR Green with low ROX) (Daejeon, Korea) according to the manufacturer's protocol. Briefly, PCR was performed in a final reaction volume of 20 µL, which included 1 µL cDNA, 1 µL forward primer and 1 µL reverse primer, and 10µL PreMIX. The PCR cycling program consisted of an initial denaturing cycle at 95°C for 15 min, followed by 40 amplification cycles of 30 s at 72°C and 15 s at T_m. PCR primers were purchased from Cosmogenetech (Seoul, Korea). Transcript levels of CYP_{3A}, iNOS, catalase, NF-kB, Bcl-2, IL-1b, TNF-α, and occludin were normalized to a house keeping gene (β-actin) as internal control. All analyses were carried out in triplicate.

Results: Transcript levels of several genes in the intestinal tract of indomethacin-treated zebrafish were more significantly altered in different ways than in distal region of the small intestine of indomethacin-treated rats. Transcripts of inducible nitric oxide synthase (an indicator of oxidative stress), B-cell lymphoma-2 (an indicator of apoptosis resistance), interleukin 1-beta and tumor necrosis fac-

Poster Abstracts

tor- α (both indicators of inflammation) increased more significantly in zebrafish than in rats. In contrast, transcripts of catalase (an indicator of oxidative stress) decreased more significantly in zebrafish than in rats. In addition, transcripts of occludin (an intestinal tight junction protein) also decreased more significantly in zebrafish than in rats.

Conclusion: Our results indicated that indomethacin induced more pronounced transcript level changes in the marker genes iNOS, Bcl-2, IL-1 β , TNF- α , catalase, and occludin in the zebrafish than in the rat, suggesting that the zebrafish may be a more sensitive model for intestinal toxicity testing than the rat.



*Poster Abstracts***P22: Silver nanoparticles: assessment of bactericidal activity against *Aeromonas salmonicida* and in vitro cytotoxicity using the MTT assay in three different fish cell lines*****Shaan Mohamed^{1,2}, El-Mahdy Magdy², El-Matbouli Mansour¹ and Saleh Mona¹***¹ *Clinical division of fish medicine, University of veterinary medicine, 1210, Vienna, Austria*² *Department of pathology, Faculty of veterinary medicine, Cairo University, Egypt*

Aeromonas salmonicida is a major pathogen affecting salmonid fish resulting in high mortalities. The global increasing demands for fish consumption resulted in greater intensification in aquaculture activities worldwide with massive usage of antibiotics. The problem of antibiotic resistance development is a major alarming concern during the latest years in both human and veterinary medicine. Genes of antibiotic resistance can be transferred from aquatic bacteria to animal and human bacteria, which imposes a great hazard on human public health. Bacterial fish diseases constitute a massive threat to the aquaculture industry. From this point arises the need for alternative antibacterial therapies to combat fish pathogens.

In this study, the antibacterial effect of silver nanoparticles (AgNPs) against *A. salmonicida* was investigated. AgNPs exhibited potent bactericidal activity against *A. salmonicida* in vitro. In vitro cytotoxicity of AgNPs at effective concentrations was investigated using a MTT assay in three different fish cell lines (Eel kidney cells-1, Fathead minnow cells and Chinook salmon embryo cells). The effects of AgNPs on cell viability were dose dependent, low concentrations of silver nanoparticles were non-cytotoxic and they exhibited antibacterial effect against *A. salmonicida*. Further in vivo studies should be conducted to assess safety of AgNPs as antibacterial therapy in aquaculture.

*Poster Abstracts***P23: The minipig: an alternative animal model for the evaluation of anti-neoplastic drugs****Manno Rosa Anna, Grasseti Andrea, Capobianco Raffaella and Oberto Germano***Research Toxicology Centre, Pomezia, Rome, Italy*

Introduction: The Beagle dog has been extensively used as a non-rodent species in anticancer drug toxicity testing, but several ethical restrictions limit its use. The aim of this study was to evaluate the feasibility of the minipig as an alternative non-rodent species for testing anticancer drugs like doxorubicin, one of the most effective anti-neoplastic agents and causing cardiotoxicity as a major side effect.

Experimental Design: Three groups of three male and three female Göttingen minipigs received 1.5 mg/kg, 3/2.3 mg/kg or vehicle at intervals of 3 weeks for 7 cycles. Due to hematological changes, the high dose of 3 mg/kg was reduced to 2.3 mg/kg from the second till the seventh cycle of doxorubicin administration. The dose levels were chosen similar to those used for human chemotherapeutic treatments and higher than those used in a preclinical toxicity study in dogs (unpublished results, 1).

Methods: Clinical laboratory and anatomic pathology evaluations were performed on all animals with special emphasis on the doxorubicin-induced cardiotoxicity.

Results: Doxorubicin administration in the minipig induced classical hematological alterations with partial reversibility in the high dose animals. The histopathological evaluation confirmed the toxicity profile seen in humans as well as in other laboratory animal species. Moreover, cardiac lesions detected in semi-thin toluidine blue-stained sections (micro- and macrovacuolation in cardiomyocytes of different anatomic regions of the heart, mainly the right and left ventricle and/or atrium) were also evident as toxic response to the doxorubicin administration. The minipig appeared to be a better clinically translatable model than the dog, as in our experience, the Beagle dog proved to be more sensitive than humans with more severe toxicity-related side effects at lower doses than those observed in this study in the minipig.

Impact statement: This study showed that the minipig had a toxicity profile more similar to humans and should be considered as the non-rodent species of first choice for future studies on anthracycline toxicity testing.

Reference:

1. Working PK, Newman MS, Sullivan T, Yarrington J. Reduction of the cardiotoxicity of doxorubicin in rabbits and dogs by encapsulation in long-circulating, pegylated liposomes. *J Pharmacol Exp Ther.* 1999;289(2):1128-33.

*Poster Abstracts***P24: Always know your vehicle: sulfuric-acid based vehicle induced nephrotoxicity and pancreas toxicity in cynomolgus monkeys.**

Friderichs-Gromoll Stephanie¹, Korte Sven¹, Kaspareit Joachim¹, Niehoff Marc¹, Romeike Annette¹ and Pfaff Tamara²

¹ Covance Preclinical Services GmbH, Münster, Germany

² AiCuris Anti-Infective Cures GmbH, Wuppertal, Germany

We report here unexpected adverse effects (like weight loss, increased WBC, and increased BUN and creatinine) observed during a maximum tolerated dose (MTD) study with Cynomolgus monkeys, following continuous intravenous infusion of a diluted sulfuric acid-based vehicle to control group animals. Histopathologic examination revealed nephropathy in the kidneys, as well as acinar degeneration and single cell necrosis in the pancreas.

The vehicle (consisting of Sulfuric acid [95 wt% in water, VWR], Sorbitol [$\geq 98.7\%$, Sigma Aldrich®], L-Arginine [free base, MW = 174.2 g/mol, $\geq 99\%$ pure, Merck KGaA 101542], and Water), used in this case study, was administered to two Cynomolgus monkeys (one male and one female, 4 to 7 years old and weighing approximately 4-7 kg) by continuous intravenous infusion for 24 hours. Both animals were fed ad libitum and dosed once daily for 2 weeks.

A high infusion rate of 10.9 mL/kg/h was applied during the first hour of dosing ("bolus" infusion), followed by 23 hours of a low infusion rate of 0.9 mL/kg/h. An Orchestra Model 500 pump (Pegasus®, flow rates 0.10 – 100 mL/h) was used for continuous intravenous infusion. The animals were anesthetized prior to implantation of the vascular access port system (VAPS). Standard (Port Hold) Titanium ports (Instech Laboratories Inc., USA) and PU-catheters (3.5 Fr CBAS®, Instech Laboratories Inc., USA) were mounted onto the animals by securing the port systems subcutaneously to the middle of the back, while inserting the catheters into the caudal vena cava. The animals received post-surgical antibiotic treatment (sulfadoxine and trimethoprim for 7 days), and were monitored clinically during a recovery period of at least 72 hours.

To maintain free catheter flow through the port system, catheters were flushed at regular intervals with a sterile physiological solution, containing 10 IU/L of heparine. Prior to the start of dosing, blood was sampled for additional hematology tests and to confirm absence of inflammatory changes.

The animals were trained and accustomed to the backpack system prior to the start of the study to ensure continuous 24-hour-infusion during the dosing period.

Continuous intravenous infusion as a route of administration was well tolerated by all animals. There were only minor histopathological findings at the intravenous application site (granulation tissue). Pathological evaluation of the animals confirmed that the vehicle described in this case study was responsible for kidney and pancreas toxicity. Consequently, an alternative vehicle (saline-based vehicle, 0.9% NaCl) was used for the subsequent fixed dose phase and follow-up regulatory studies.

*Poster Abstracts***P25: Comparison of Green Fluorescent Protein (GFP) fluorescence intensity and tissue quality using two fixation methods by immersion*****Lejeune Typhaine, Herman Félicie and Tellier Pierre****Charles River Laboratories Montreal ULC, Senneville site, Quebec, Canada*

As new drugs in development are geared towards gene therapy, GFP is being used as a reporter gene to ensure that the future therapeutic gene will be expressed in targeted cells. Therefore, monitoring GFP expression accurately is an important issue. The fastest and most cost-effective way to monitor GFP expression is by direct fluorescence microscopy to detect its autofluorescence. The fixation method of choice for GFP detection by direct fluorescence microscopy (i.e. to ensure good tissue quality and good fluorescence intensity) is by perfusion with 4% paraformaldehyde which is not always available in terms of equipment and cost. This poster compares two fixation methods by immersion and their results in terms of tissue quality vs GFP fluorescence intensity in rats.

GFP transgenic Sprague Dawley rats were necropsied and several tissues were retained and fixed by immersion in either 4% paraformaldehyde or 4% formalin/ 7% picric acid for 2, 14 or 22 hours. Following fixation, tissues were cryoprotected in sucrose, embedded in OCT and frozen. 8 µm sections were cut and mounted on glass slides with an anti-fading mounting media.

Direct detection of GFP expression under fluorescence microscopy could be achieved by immersion fixation of tissues for up to 22 hours followed by freezing. Even though formalin/picric acid is not a routine fixative, it should be considered when GFP expression is to be evaluated as it allows detection of GFP by direct fluorescence microscopy with very good tissue quality and therefore, can be a more simple and economic alternative to fixation by perfusion. Immersion in paraformaldehyde remains a good option in terms of fluorescence intensity but tissue quality is highly variable. Furthermore, both fixation methods still allowed immunohistochemistry to be performed efficiently on frozen sections, even after long term storage.

*Poster Abstracts***P26: Use of a multiple low dose regimen of non-pharmaceutical grade streptozotocin results in consistently elevated blood glucose levels and a lower incidence and severity of detectable, clinical effects in male C57BL/6 mice when given intraperitoneally**

Blas-Machado Uriel², Storves Kathleen P.¹, Lacefield Lauren², Buac Kristina¹, Hutcheson Jessica¹, Harvey Stephen B.², Sanchez Susan², Chronos Nicolas¹ and Chavan Surendra¹

¹ ViCapsys, Athens, GA, USA

² Department of Pathology, College of Veterinary Medicine, University of Georgia, Athens, GA, USA

Streptozotocin (STZ), a DNA alkylating agent that destroys the b-cells of the pancreas, is commonly used to induce insulin-dependent diabetes mellitus (IDDM or Type 1 diabetes). Animal welfare regulations promote the use of pharmaceutical grade agents over non-pharmaceutical grade products, unless scientifically justified and approved by the institutional animal care and use committee. Animal models using STZ often do not result in 100% induction of diabetes, and dosing regimens range from one bolus dose to multiple low doses. In the current study, the hypothesis was that pharmaceutical grade STZ provides a greater IDDM induction percentage with less adverse effects than non-pharmaceutical grade STZ, and that multiple low doses would result in less toxicity than a single high bolus dose.

Fifty, 8-12-week-old, male C57BL/6 mice were used. Groups 1 and 3 received 3 doses of pharmaceutical and non-pharmaceutical grade STZ at 83 mg/kg intraperitoneally (IP), respectively. Groups 2 and 4 received a single dose of 250 mg/kg (IP) pharmaceutical and non-pharmaceutical grade STZ, respectively. Groups 5 and 6 served as control groups and received 83 and 250 mg/kg of sodium citrate IP, respectively. Animals were evaluated over a 6-week-period, with body weight and blood glucose readings as well as collection of pancreas, liver, and kidneys at necropsy for histopathology. All animals in the low dose pharmaceutical and non-pharmaceutical groups (groups 1 and 3) achieved and maintained blood glucose levels above 200 mg/dL and survived for the duration of the study without overt clinical signs or significant weight loss. All animals in the high dose pharmaceutical and non-pharmaceutical groups (groups 2 and 4) required early euthanasia due to declining physical condition and severe weight loss. Biologically significant tissue alterations were detected in treated animals, but not in controls. The main changes in the pancreas consisted of decreased numbers and size of the islets and loss of zymogen granules. In the liver, significant findings consisted of hepatocellular degeneration (hydropic and vacuolar) and necrosis. The tissue alterations noted in the kidneys consisted of tubular degeneration and necrosis and hydronephrosis. The incidence, type, and severity of the tissue changes were similar regardless of the type of STZ used or dosing regimen. The results indicate that non-pharmaceutical and pharmaceutical grades STZ have similar induction rates of IDDM and toxicities. Moreover, results indicate that IP administration of a single, high bolus dose of STZ from either grade can result in severe, adverse clinical signs that may require early euthanasia.

In conclusion, the use of a multiple low dose regimen results in consistently elevated blood glucose levels and a lower incidence and severity of clinical, adverse effects in male, 8-12-week-old, C57BL/6 mice when given IP.

*Poster Abstracts***P27: An in vivo chicken model for fluoroquinolone-associated degenerative tendinopathy****Blas-Machado Uriel^{1,2}, Olaniyi Moshood³, Zhang Jian¹ and Halper Jaroslava T.¹**¹ *Department of Pathology and*² *Athens Veterinary Diagnostic Laboratory College of Veterinary Medicine, University of Georgia, Athens, GA, 30602, USA*³ *Department of Veterinary Pathology, Federal University of Agriculture, Abeokuta, Nigeria*

Degenerative tendon disease or tendinopathy refers to the clinical condition of activity-related pain, focal tendon tenderness, and intratendinous imaging changes. Tendinosis or tendon degeneration refers to the histopathological alterations that occur in tendon tissue. Fluoroquinolones belong to a class of antibiotics (e.g., norfloxacin, ciprofloxacin, levofloxacin, moxifloxacin, enrofloxacin) used to treat a wide range of infections because of its excellent gastrointestinal absorption, superior tissue penetration, and broad-spectrum activity. Fluoroquinolones have been associated with degenerative tendon disease first reported in 1983, in a 56-year-old renal transplant patient, who was treated with norfloxacin for a urinary tract infection with septicemia and subsequently developed gastrocnemius tendon tendinopathy. Spontaneous tendon degeneration in humans is likely worsened with use of fluoroquinolones. Reported human risk factors include: systemic corticosteroid therapy, renal failure, diabetes mellitus, sport activity, history of musculoskeletal disorders and age (> 60 year-old). Exact mechanism of fluoroquinolone-associated degenerative tendinopathy remains to be elucidated. The therapeutic mode of action is thought to be due to inhibition of bacterial DNA gyrase (a type II topoisomerase), which is directly involved in DNA replication and cell division. Rapid onset of tendon injury induced by fluoroquinolones in animal studies suggests direct collagen toxicity. They inhibit tenocyte proliferation and cell migration, affects proteoglycan synthesis and fibrillogenesis, and leads to changes in extracellular matrix composition, decreased mitochondrial activity, and enhanced matrix or tissue metalloproteinase activity. The objective of the study was to evaluate the chicken as an in vivo model for chemically-induced degenerative tendinopathy, in order to further the understanding of tendinosis and its underlying causes in an alternative animal species.

Sixty, 1 day-old, Avian reovirus-free White Leghorn male chickens were used. Forty eight chickens were exposed to enrofloxacin either in drinking water [10 mg/kg or 50 mg/kg] or by subcutaneous injection [10 mg/kg or 50 mg/kg] for 7 days, and 12 chickens were exposed to enrofloxacin-free drinking water and/or injected with physiological saline solution to serve as controls. To identify the potential changes in the gastrocnemius tendon (GT), chickens were necropsied at experimental day 1, 14, and 42. The response of the GT to enrofloxacin was followed by clinical observation, necropsy, histopathology, and Decorin and Collagen I immunohistochemistry. In a follow-up experiment, gastrocnemius tendon fibers from control and treated birds were examined ultrastructurally and their fiber diameter measured and compared. Gross lesions were absent in all birds. At day 14 and 42, enrofloxacin-treated chickens developed significant tendon degeneration regardless of the dose or treatment route. Immunohistochemical detection of Decorin and Collagen I was diminished. Ultrastructurally, the treated tendon fibers were on average 35.88 nm thicker than fibers in the untreated control group ($p < 0.0001$).

In conclusion, daily oral or subcutaneous enrofloxacin administration at 10 mg/kg for 7 days leads to

Poster Abstracts

histopathological changes in the GT of 1 day-old White Leghorn male chickens; thus, suggesting that chickens are a suitable in vivo model for the study of chemically-induced (fluoroquinolone) GT degeneration. Additional research on clinical and functional parameters and composition of extracellular matrix is warranted.



*Poster Abstracts***P28: Interpreting elevations of cardiac troponins using high sensitivity cardiac troponin (hs-cTn) assays in preclinical toxicology. When is an elevation adverse?***Jacobsen M¹, Cotton P¹, Cartwright J¹, Barnes J¹**¹ Drug Safety and Metabolism, AstraZeneca, Cambridge, UK*

In the field of toxicology, numerous publications describe the use of cardiac troponins (cTn) to detect cardiotoxicity in laboratory species. In 2012, the FDA Biomarker Qualification Review Team accepted them as ‘qualified’ for use in non-clinical toxicology studies within certain contexts. The majority of cTn assays deployed pre-clinically were developed for use in humans, resulting in increasing levels of sensitivity as the assays evolved. Thus, current high sensitivity cardiac troponin (hs-cTn) assays often have a Lower Limit of Quantification (LLQ) in the nanogram or picogram range, allowing the detection of very small elevations in cTn.

Limited published information exists for assay-specific cTn reference ranges. Published validation studies have typically used cardiotoxins at doses that produced histopathological lesions in the heart with correlative and often significant increases in absolute plasma or serum cTn values. Published data using an ultra-sensitive cTnI assay to compare baseline values measured at a single time point in four rat strains also demonstrated considerable baseline variation¹.

Data from AstraZeneca’s experience utilizing the Siemens (formerly Bayer) cTnI Ultra assay is presented which highlights several issues, including: significant intra- and inter-animal baseline variation in both rats and dogs, particularly during acclimatization and early sampling time points; significant cTn elevations when compared to the assay LLQ without correlative cardiac histopathology; the confounding effect of spontaneous cardiac pathology, particularly in rats; and, finally, the challenge of detecting structural cardiotoxins in routine toxicology studies when evaluating a limited number of heart sections.

In addition, the authors provide their perspective on the definition of a toxicologically significant elevation in cTn, especially in the absence of cardiac histopathology, and the appropriate use of hs-cTn assay data when defining adverse effect levels.

Reference:

1. Herman E, Knapton A, Rosen E, Zhang J, Estis J, Agee S, Lu Q, Todd J, Lipshultz S: Baseline Serum Cardiac Troponin I Concentrations in Sprague-Dawley, Spontaneous Hypertensive, Wistar, Wistar-Kyoto, and Fisher Rats as Determined with an Ultrasensitive Immunoassay. *Toxicologic Pathology*, 39: 653-663, 2011.

*Poster Abstracts***P29: Spontaneous age-related lesions of rat kidney fornices**

Seely John Curtis¹, Willson Gabrielle A.¹, Tomonari Yuki², Kurotaki Tetsuro², Sato Junko², Doi Takuya², Kokoshima Hiroko², Kanno Takeshi² and Tsuchitani Minoru²

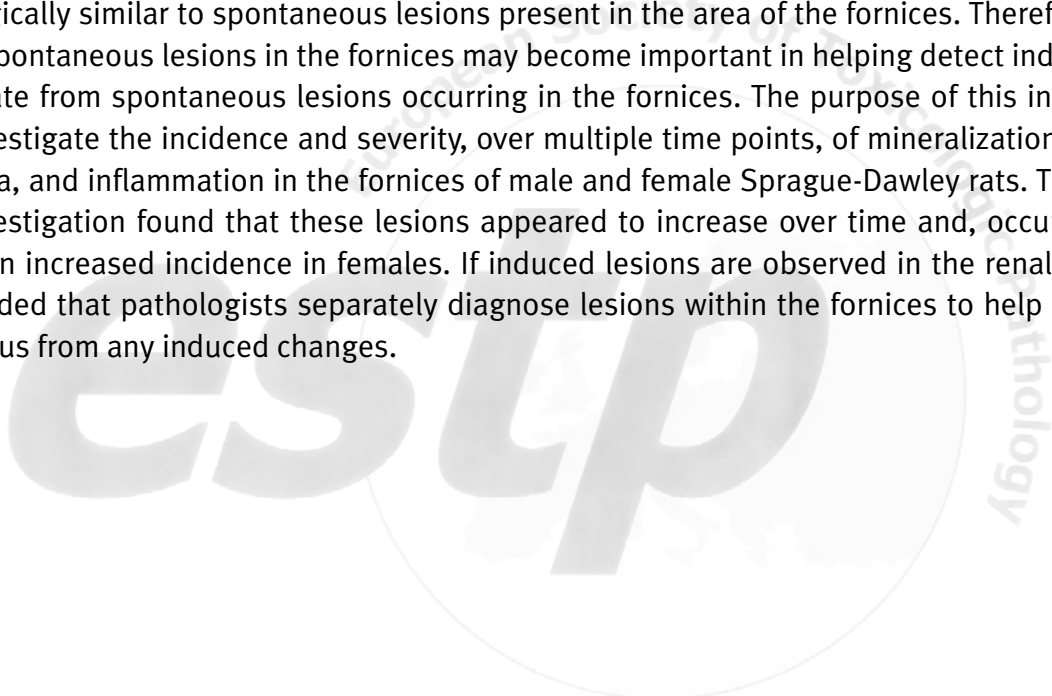
¹ *Experimental Pathology Laboratories, Inc., Research Triangle Park, NC, 27709, USA*

² *LSI Medience Corporation, Kamisu, Ibaraki, Japan*

This presentation represents work that was recently published in the journal *Toxicologic Pathology*:

Tomonari Y, Kurotaki T, Sato T, Doi T, Kokoshima H, Kanno T, Tsuchitani M, and Seely JC. 2016. Spontaneous age-related lesions of the kidney fornices in Sprague-Dawley rats. *Toxicol Pathol* 44, 226-232.

Vault-like folds which extend into the upper pelvis in rats are called fornices. Fornices increase the surface area of the renal pelvis, thereby increasing exposure of pelvic urine to the renal medulla thus having a role in urine concentration mechanisms. Induced lesions of the rat kidney pelvis may appear morphologically similar to spontaneous lesions present in the area of the fornices. Therefore, understanding spontaneous lesions in the fornices may become important in helping detect induced changes separate from spontaneous lesions occurring in the fornices. The purpose of this investigation was to investigate the incidence and severity, over multiple time points, of mineralization, epithelial hyperplasia, and inflammation in the fornices of male and female Sprague-Dawley rats. The findings of this investigation found that these lesions appeared to increase over time and, occurred earlier and with an increased incidence in females. If induced lesions are observed in the renal pelvis it is recommended that pathologists separately diagnose lesions within the fornices to help distinguish spontaneous from any induced changes.



*Poster Abstracts***P30: Case report: congenital superior ectopic kidney in a cynomolgus monkey**

Qiao Junwen¹, Thurman Dale², Lu Henglei², Sun Jingjun¹, Tan Rongrong¹, Lan Xiuhua¹, Sheng Hua¹, Wu Chunyan¹, Shao Jun¹ and Ren Jin¹

¹ Center for Drug Safety Evaluation and Research, Shanghai Institute of Materia Medica, Chinese Academy of Sciences, Shanghai, China

² Global Pathology Services, West Chester, Philadelphia, USA

To our knowledge, superior kidney ectopia has not been reported in a cynomolgus monkey. In this case report, we document a case of congenital superior kidney ectopia in a 4-year old cynomolgus monkey. No corresponding clinical pathology or microscopic abnormalities were evident.

A 4-year-old male cynomolgus monkey, with no abnormalities observed during the in-life phase, was submitted for routine scheduled necropsy at the termination of a preclinical safety study. Upon opening the abdominal and thoracic cavities, the otherwise macroscopically normal, left kidney was found to be located anteriorly and partly through the diaphragm with $\frac{3}{4}$ of the kidney in the thoracic cavity and $\frac{1}{4}$ in the abdominal cavity. The kidney was attached dorsally to the ventral surfaces of the ribs and tightly adhered to the dorsal aspect of the diaphragm. The left adrenal gland migrated with the kidney and was located between the kidney and the ribs. Integrity of the thoracic cavity remained intact because of fusion with the diaphragm and tissues adjacent to the misplaced kidney. The left kidney was slightly larger than the right kidney. All lung lobes remained intact and there was no atelectasis or compression due to the misplaced kidney. The ureter was elongated to accommodate the excessive distance between the misplaced kidney and the urinary bladder. Clinical pathology results including urinalysis, serum urea and creatinine levels were within normal ranges. Microscopic examination showed no morphological anomalies. No history of trauma or urologic disease was reported.

Discussion: In humans, superior kidney ectopia is a very rare congenital malformation, with only about 50 cases reported in the literature [1]. The terminology “superior” was used here based on the suggested diagnostic criteria by N’Guessen et al [2]. Superior kidney ectopia refers to either a partial or complete protrusion of the kidney through the diaphragm and into the posterior mediastinum. To our knowledge, this is the first case of superior kidney ectopia reported in the cynomolgus monkey. Superior ectopic kidneys in humans are usually asymptomatic and functionally normal [3]. Awareness of this congenital change in cynomolgus monkeys used in safety assessment studies may prevent unnecessary extensive investigation by the veterinarian and toxicologic pathologist.

References

1. Donat SM and ante PE. Intrathoracic kidneys: a case report with a review of the world literature. The Journal of Urology 1988; 140:131-3.
2. Gabbriel N’Guessen, F.Douglas Stephens, and James Pick. Congenital superior ectopic (thoracic) kidney. Urology, September 1984, Volume XXIV, number 3.
3. Clarkson LM, and Potter S. An unusual thoracic mass. The British Journal of Radiology 2009; 82:e27-e28.

*Poster Abstracts***P31: The route of exposure influences nasal lesion distribution in rats in NTP Studies.**

Cimon Karen Y.¹, Moore Rebecca R.², Miller Rodney A.¹, Willson Gabrielle A.¹, Pandiri Arun R.³ and Malarkey David E.³

¹ *Experimental Pathology Laboratories, Inc., Research Triangle Park, NC, USA*

² *Integrated Laboratory Systems, Research Triangle Park, NC, USA*

³ *Cellular and Molecular Pathology Branch, Division of the National Toxicology Program, National Institute of Environmental Health Sciences, Research Triangle Park, NC, USA*

Introduction: Nasal toxicity is not only observed in inhalation exposure studies but also in drinking water and gavage studies. Nasal toxicants may act systemically, directly, or both and the occurrence and distribution of nasal lesions may provide clues to the pathogenesis. This review focuses on nasal lesion occurrence, features, and distribution as seen in a chronic whole body inhalation study compared to two drinking water and three gavage studies with nasal toxicity conducted by the NTP.

Methods: We examined all 3 routine sections of nose from all control and high dose male and female F344N rats. The general distribution of nasal and nasopharyngeal duct lesions was recorded and mapped as predominately anterior or posterior; dorsal or ventral; and unilateral or bilateral.

Results: Nasal lesions in the inhalation study were of varying severity, occurred predominately as bilateral and dorsal; more frequently in the anterior sections (98%) of the nose and less often (18%) in the most posterior section of the nasal cavity. In the 2 drinking water studies, the nasal lesions were uniformly observed in the middle and posterior nasal sections; only olfactory epithelium was affected; and lesions had a dorsal and bilateral distribution in 90% or 100% of the rats. In the 3 gavage studies, the nasal lesions varied in character and distribution; tended to be more posterior and ventral, and were predominately unilateral. Lesions in the nasopharyngeal duct occurred irregularly and only in the gavage studies. The changes in the gavage studies were similar in male and female rats.

Impact Statement: Most inhalation or systemically induced nasal effects are uniform in tissue specificity and/or distribution, thus affecting tissue in anatomically consistent manner. The nasal lesions in the 3 gavage studies resembled those described for gavage-related reflux. When patterns of distribution of nasal lesions are not uniform or not consistent with known patterns of induced lesions, then one must consider an alternative pathogenesis, e.g., gastric reflux, gavage accidents or aspiration.

*Poster Abstracts***P32: PEG accumulation in cells: adverse or non-adverse?**

**Braendli-Baiocco Annamaria¹, Albassam Mudher², Lenz Barbara¹, Mikaelian Igor³
and Tyagi Gaurav²**

¹ Roche Innovation Center, Basel, Switzerland

² Roche Innovation Center, New York, NY, USA

³ Gilead Sciences, Foster City, CA, USA

Conjugation to polyethylene glycol (PEG), i.e. PEGylation, is an effective strategy to increase half-life and decrease immunogenicity of therapeutic protein and peptides. There are currently 11 approved PEGylated pharmaceuticals on the market.

Cellular vacuolation is a common histologic finding in toxicology studies with PEGylated compounds and is due to the accumulation of PEG into the lysosomes. The vacuolation is observed in phagocytic and parenchymal cells, and is dose- and duration-dependent.

A PEGylated peptide was administered subcutaneously to rats and monkeys in multiple toxicology studies for up to 52 weeks. Investigations included standard in-life parameters, drug exposure, clinical pathology, histopathology, immunohistochemistry (IHC) for PEG, and Fluoro Jade to assess neuronal injury.

Cytoplasmic vacuolation was observed in several tissues of both species including choroid plexus, epithelium of the ciliary body, kidney, liver, pituitary, thyroid and parathyroid glands, adrenals glands, mammary gland, prostate, and macrophages of several tissues including macrophages at injection site. Vacuolation was partially reversible in these organs. Presence of PEG was shown by IHC in the affected cells. In the brain and spinal cord of the 4-week rat and monkey studies, there was PEG immunolabeling without concomitant presence of vacuoles whereas there was neuronal vacuolation in the 26-week rat and in the 52-week NHP studies consistently associated with PEG immunolabeling. Vacuolation persisted after 26-week recovery and was observed in additional neurons of central nervous system. In all affected organs, vacuolation was not associated with changes such degeneration, inflammation, or necrosis. In particular, in the brain, neuronal vacuolation was not associated with neuronal damage as confirmed by Fluoro Jade stain.

Cytoplasmic vacuolation was considered to be due to the accumulation of PEG into the cells and was dependent from the dose and duration of the treatment. Based on the findings presented in this interactive poster, the conference delegates are asked to give their opinion about the adversity of the findings.

*Poster Abstracts***P33: Changes in preclinical liver biological data in a Clofibrate toxicity study in male Wistar rats: adverse or not adverse?**

Maliver P.¹, Festag M.¹, Christen F.¹, Lenz B.¹ and Winter Michael¹.

¹ Roche Pharma Research and Early Development (pRED), Pharmaceutical Sciences, Roche Innovation Center, Basel, Switzerland

Background: Adversity of clinical pathology changes and/or microscopic findings are often difficult to define, depending on subjectivity of the study pathologist. The poster describes liver changes at different doses of Clofibrate. Clofibrate, as a (PPAR)- α agonist, upregulates cellular alanine aminotransferase (ALT) activity and therefore can increase serum ALT concentration in the absence of hepatocellular damage. Nevertheless at toxic dose, clofibrate induces liver hepatocellular injury in rats. The combination of several markers (GLDH, Arginase-1, mi-RNA122) as well as ALT were evaluated as indicators for hepatocellular injury/adversity, in addition to liver weights and microscopic evaluation. You are invited to give your opinion about the toxicological relevance of these changes.

Experimental procedure: Male Han Wistar rats received oral (gavage) doses of 0, 200, 400 or 750 mg/kg/day for up to seven consecutive days at 10 mL/kg body weight. Rats at 750 mg/kg/day dosed for 2 days and one rat at 400 mg/kg/day were sacrificed for humane reasons on days 3 or 4. Blood sampling for biomarkers and standard clinical pathology assessment were conducted on days 3/4 and 8. Histopathological examination was performed on liver, heart, diaphragm, soleus muscle, kidney and quadriceps muscle tissues.

Results: Increased liver weights (BW ratios) were observed at \geq 200 mg/kg (minimum of +46%). Increased liver BW ratios as well as not dose-dependently decreased cholesterol levels confirmed clofibrate-related liver changes in all treated groups, independently of the day of sacrifice (days 3/4 or 8). Dose dependent hepatocellular hypertrophy was noted in all treated groups. Increased incidence of hepatocellular mitoses was also observed in all treated groups. On days 3/4, increased activities of ALT, Arginase-1, (and GLDH to a lesser extent) in serum as well as increased miRNA122 expression levels were noted at 400 and/or 750 mg/kg/day.

Conclusion: You are asked to give your opinion about the adversity or non-adversity of the different biological changes noted in this study:

Do you consider the extent of the increased liver weights (minimum of +46%) to be adverse per se?

Do you consider histopathologic changes (hypertrophy and mitoses) as adverse?

Do you consider increases of multiple biomarkers related to liver injury noted on days 3/4, to be adverse per se, and if yes at which dose level?

Taken together, do you consider the changes in liver weights, clinical pathology parameters and microscopic findings at 200, 400 and/or 750mg/kg dose level as adverse?

From Health to Beauty

With our 10,000 employees worldwide, we design and develop innovative solutions that contribute to the well-being of all, from health to beauty. We achieve this by cooperating with health care professionals, our long-standing trusted partners, by drawing relentless inspiration from nature, and by placing pharmaceutical ethics at the very heart of our operations. We focus our research and manufacturing activities in South-West France where our roots lie. We are proud to belong to a public-interest organization, the Pierre Fabre Foundation, which is dedicated to improving access to high-quality health care and medication in the poorest countries.




Pierre Fabre
Médicament

Pierre Fabre
HEALTH CARE

Pierre Fabre
ORAL CARE

naturactive
LABORATOIRES PIERRE FABRE

Pierre Fabre
DERMATOLOGIE

DUCRAY
LABORATOIRES DERMATOLOGIQUES

EAU THERMALE
Avène

DARROW
DERMO COSMETIQUES

GLYSTONE

A-DERMA
AVOINE RHEALBA®

LABORATOIRES
KLORANE
SOINANT À PRÉCISION

ELANCYL
PARIS

GALÉNIC
PARIS


RENÉ
FURTERER
PARIS



Pierre Fabre

Many Thanks to our exhibitors



Many Thanks to our sponsors



**Please visit
www.estp-finalprogram.com
for an online version of this
document**